

SIGNS AND SYMPTOMS OF URINARY SYSTEM DISEASES

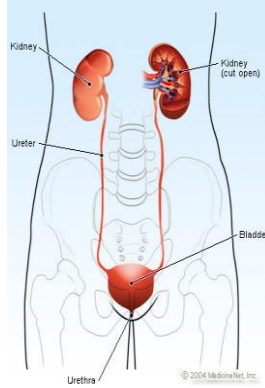
(urinary syndrome, nephrotic syndrome, nephritic syndrome,
urinary tract obstruction syndrome, hypertensive syndrome)

LECTURE IN INTERNAL MEDICINE PROPAEDEUTICS 2017/2018

M. Yabluchansky, L. Bogun, L.Martymianova, O. Bychkova, N. Lysenko, M. Brynza
V.N. Karazin National University Medical School' Internal Medicine Dept.

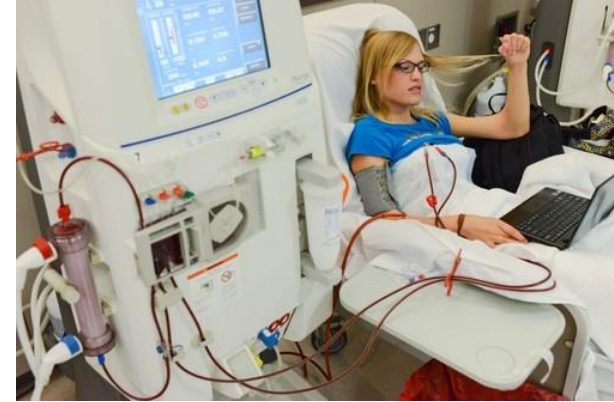Plan of the lecture

- The importance(value) of a human kidney
- Urinary system diseases' syndromes (urinary syndrome, nephrotic syndrome, nephritic syndrome, urinary tract obstruction syndrome, hypertensive syndrome)
- Reminder (how do kidneys work, the primary function, purpose)
- History-taking & patient's examination
- Spectrum of urinary system diseases
- Urinary system diseases' symptoms



The importance(value) of a human kidney

The human kidney is the body's filter. It cleans 180 liters of liquid per day, retaining the good stuff and expelling the bad. Most fortuitously, humans are born with two kidneys. If one of them becomes damaged, the other one can pick up the slack. If both kidneys fail, however, body will be filled with harmful toxins. Without medical intervention, such patients will die within several weeks

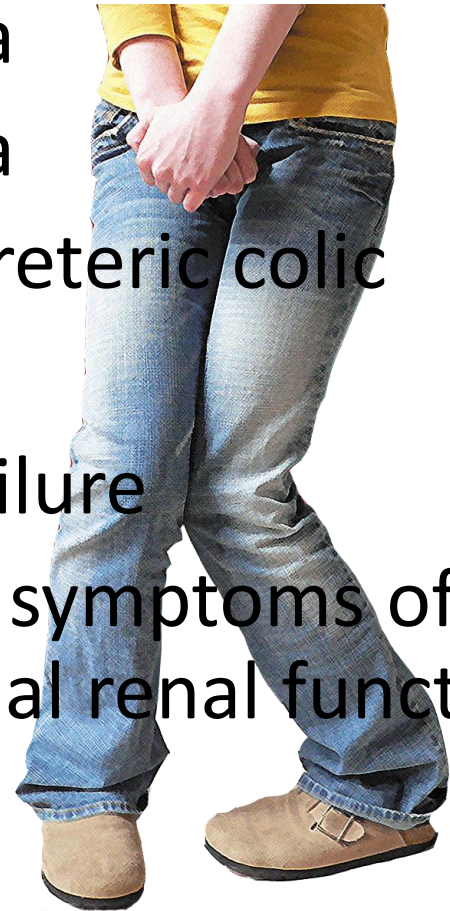

Spectrum of urinary system diseases

- Congenital abnormalities
- Interstitial nephritis
- Glomerulonephritis
- Cystic kidney disease
- Renal vascular disease
- Nephrotic syndrome
- Renal failure
- Infections of the urinary tract
- Obstruction of the urinary tract
- Urinary tract calculi and nephrocalcinosis
- Malignancy of the urinary tract e.g. CA bladder
- Incontinence

Urinary system diseases' symptoms

- pain
- proteinuria
- azotaemia, leading to uraemia
- haematuria
- urinary casts
- hypertension
- oliguria or anuria
- oedema
- polyuria
- renal/ureteric colic
- dysuria
- renal failure
- general symptoms of abnormal renal function



Urinary syndrome: definition, symptoms

Definition: quantitative and qualitative changes in urine

Symptoms: changes in the volume and composition of the urine output; changes in the rhythm of urinary excretion; changes in the volume and composition of the blood



Nephrotic syndrome: definition

Clinical and laboratory syndrome characterized by massive proteinuria, which lead to hypoproteinemia (hypoalbuminemia), hyperlipidemia and pitting edema in results from increased permeability of glomerular basement membrane (GBM) to plasma protein

Nephrotic syndrome: criteria

- hematuria (RBC in urine, gross hematuria)
- hypertension ($\geq 140/90$ mmHg)
- azotemia (renal insufficiency - increased level of serum BUN, Cr)
- hypocomplementemia (decreased level of serum C3)

Nephrotic syndrome: types

- idiopathic (90%)
- secondary (10%, anaphylactoid purpura , systemic lupus erythematosus, HBV infection, act.)
- congenital

Nephrotic syndrome: pathophysiology

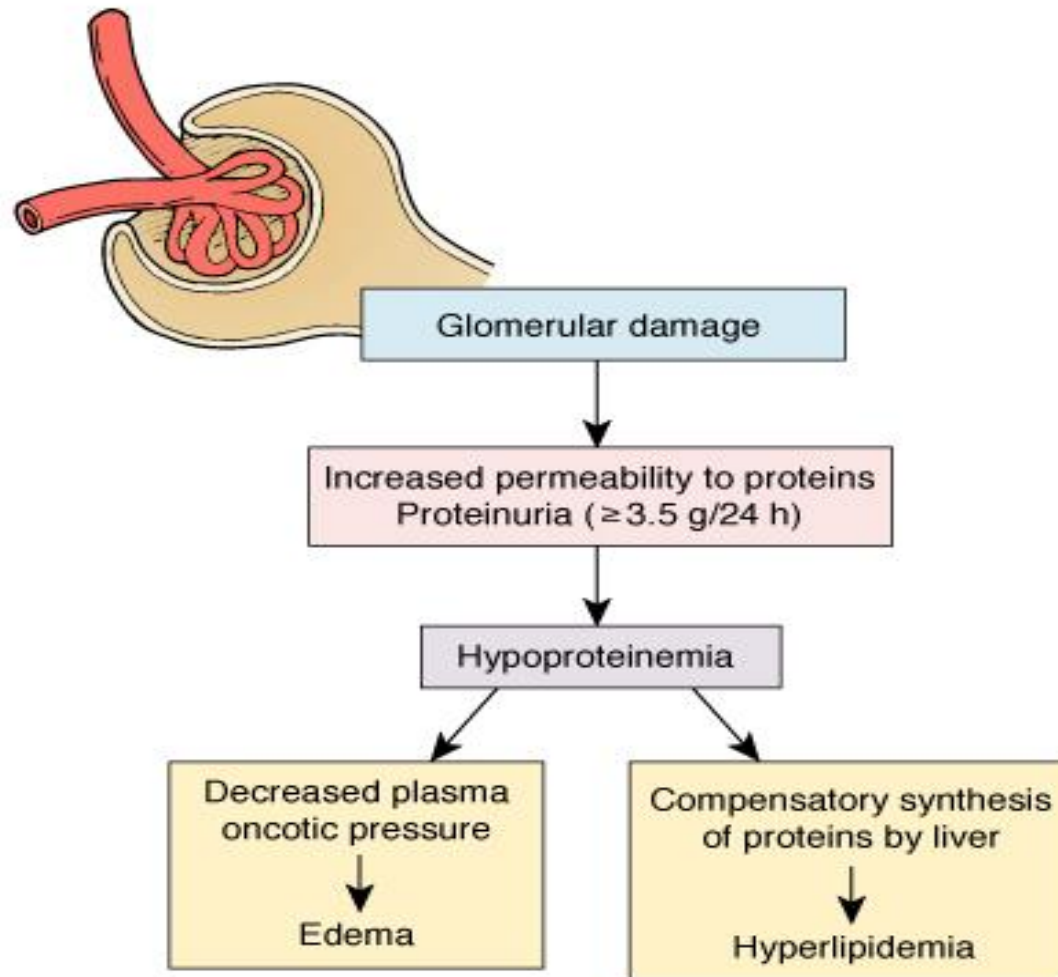


Figure 35-10 Pathophysiology of the nephrotic syndrome.

Nephrotic syndrome: degrees of proteinuria

- mild $< 0.5 \text{ g/m}^2/\text{day}$
- moderate $0.5 - 2 \text{ g/m}^2/\text{day}$
- severe $> 2 \text{ g/m}^2/\text{day}$

Nephrotic syndrome: types of proteinuria

- Selective (where proteins of low molecular weight, such as albumin, are excreted more readily than protein of HMW (High Molecular Weight))
- Non selective (LMW (Low Molecular Weight)+HMW are lost in urine)

Nephrotic syndrome: symptoms

Edema (varying degrees): local (edema of face (facial edema), edema around eyes (periorbital swelling) , in lower extremities), generalized (anasarca), edema of penis and scrotum

Other clinical symptoms: fatigue, lethargy, loss of appetite, nausea and vomiting ,abdominal pain , diarrhea, body weight increase, urine output decrease, pleural effusion (respiratory distress)

Nephrotic syndrome: tests, differential diagnosis

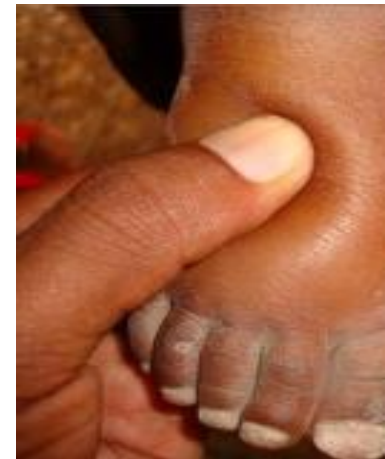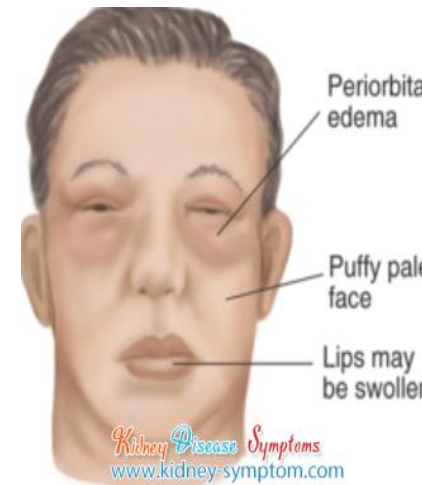
Blood tests (serum protein < 5.5 gm/dL , albumin < 2.5 gm/dL, cholesterol > 220 mg/dl)

Urine tests (proteinuria, oliguria (during stage of edema formation), microscopic hematuria 20%, large number of hyaline casts)

Differential diagnosis of generalized edema

Main in nephro^Otic syndrome (all words contain letter ^O)

1. Massive pro^Oteinuria
2. Hypo^Opro^Oteinemia (peeing ^Out albumin)
3. ^Oedema (^Oncotic pressure in the blood goes down)
4. Hypercho^Olesterolemia (hyperlipidemia/hyperlipiduria)
5. Hyperco^Oagulable state (throm^Obotic and throm^Oboembolic complications)



Nephrotic syndrome: USMLE test 1

- (M1.RL.70) A 7-year-old male suffers from generalized edema. Urine protein excretion is 5.2 g over 24 hours and serum analysis reveals hyperlipidemia. The patient responds to treatment with prednisone, and, 8 weeks later, his urine does not contain measurable protein. If a kidney biopsy had been performed while the patient's condition was pathologic, which of the following would you expect to find upon glomerular electron microscopy:
- 1. Effacement of podocyte foot processes, 2. Subepithelial 'spike and dome' deposits, 3. Subepithelial humps, 4. Thin glomerular basement membrane
5. Subendothelial thickening

Nephrotic syndrome: USMLE test 2

- A 57-year-old female visits her primary care physician with 2+ pitting edema in her legs. She takes no medications and does not use alcohol, tobacco, or illicit drugs. 4.5 grams of protein are collected during 24-hour urine excretion. A kidney biopsy is obtained. Examination with light microscopy shows diffuse thickening of the glomerular basement membrane. Electron microscopy shows subepithelial spike and dome deposits. Which of the following is the most likely diagnosis:
 1. Minimal change disease,
 2. Postinfectious glomerulonephritis,
 3. Focal segmental glomerulosclerosis
 4. Rapidly progressive glomerulonephritis,
 5. Membranous glomerulopathy

Nephrotic syndrome: USMLE test 3

- (M1.RL.84) A 6-year-old girl presents to your clinic two weeks after receiving a routine immunization in preparation for a trip overseas. Periorbital edema is present on exam and 24 hour urine collection shows excretion of 4.3 grams of protein/day. Which pathological change would likely be seen on microscopy?
- 1. Linear IgG deposition on light microscopy, 2. IgA-immune complexes in the mesangium on electron microscopy, 3. “Tram-track” appearance on light microscopy, 4. Subepithelial deposits with “spike and dome” appearance on electron microscopy, 5. Podocyte effacement on electron microscopy

Nephritic syndrome: definition

Clinical and laboratory syndrome associated with disorders affecting the kidneys, more specifically glomerular structures, and characterized by having a thin glomerular basement membrane and small pores in the podocytes of the glomerulus, large enough to permit proteins (proteinuria) and red blood cells (hematuria) to pass into the urine

Nephritic syndrome: criteria

- hematuria , with red blood cell (RBC) casts present in the urine
- proteinuria (<3.5 g/day)
- hypertension
- uremia, due to retention of waste products
- variable renal insufficiency, with azotemia, oliguria (low urine output <400 mL/day)

Nephritic syndrome: types

- post-streptococcal glomerulonephritis
- crescentic glomerulonephritis (rapidly progressive glomerulonephritis)

Nephritic syndrome

(characterized by inflammation; both words contain letter i)

Nephritic syndrome features **PHARAOH**

Proteinuria

Haematuria


Azotaemia (elevated blood nitrogen levels)

Red blood cell casts

Anti-streptolysin O titres if post-streptococcal infection

Oliguria (output $<0.5\text{ml/kg/hour}$)

Hypertension



Nephritic syndrome: USMLE test 1

- (M1.RL.11) Multiple patients present to your office with hematuria following an outbreak of Group A Streptococcus. Biopsy reveals that all of the patients have the same disease, characterized by large, hypercellular glomeruli with neutrophil infiltration. Which patient has the best prognosis?
- 1. 65-year-old nulliparous woman, 2. 50-year-old man with a history of strep infection, 3. 8-year-old boy who undergoes no treatment, 4. 38-year-old man with sickle cell trait, 5. 18-year-old man treated with corticosteroids

Nephritic syndrome: USMLE test 2

- A 10-year-old boy presents to your office with cola-colored urine and periorbital edema. His mother is extremely concerned, especially given that her son has been entirely healthy except for a sore throat a few weeks ago. Which of the following would you be LEAST likely to observe on a kidney biopsy of this patient?
- 1. "Lumpy-bumpy" appearance on immunofluorescence, 2. Subepithelial electron dense deposits on electron microscopy, 3. Polyclonal IgG and C3 deposition on immunofluorescence, 4. Linear IgG deposition along the basement membrane on immunofluorescence , 5. Large, hypercellular glomeruli on light microscopy

Nephritic syndrome: USMLE test 3

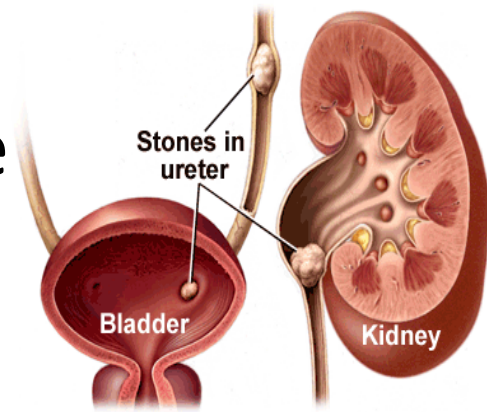
- (M1.RL.35) A 6-year-old boy presents to your office with hematuria. Two weeks ago the patient had symptoms of a sore throat and fever. Although physical exam is unremarkable, laboratory results show a decreased serum C3 level and an elevated anti-DNAse B titer. Which of the following would you most expect to see on renal biopsy?
- 1. Large, hypercellular glomeruli on light microscopy,
- 2. Polyclonal IgA deposition on immunofluorescence,
- 3. Immune complex deposits with a "spike and dome" appearance on electron microscopy,
- 4. Wirelooping and hyaline thrombi on light microscopy,
- 5. Antibodies to GBM resulting in a linear immunofluorescence pattern

Nephritic syndrome: USMLE test 4

- (M1.RL.67) A 21-year-old male presents to your office with hematuria 3 days after the onset of a productive cough and fever. Following renal biopsy, immunofluorescence shows granular IgA deposits in the glomerular mesangium. Which of the following do you suspect in this patient?
- 1. Lipoid nephrosis, 2. Berger's disease, 3. Poststreptococcal glomerulonephritis, 4. Systemic lupus erythematosus, 5. HIV infection

Urinary tract obstruction syndrome

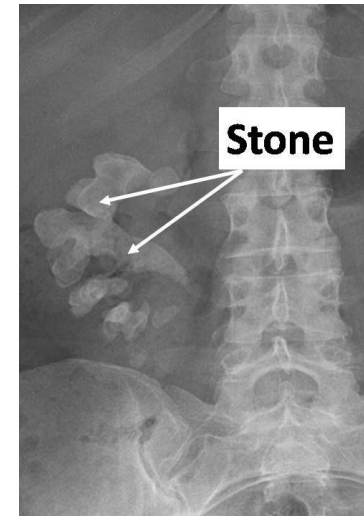- urinary tract obstruction can occur at any point in the urinary tract, from the kidneys to the urethral meatus
- it can develop secondary to calculi, tumors, strictures, anatomical abnormalities, or functional abnormalities
- obstructive uropathy can result in pain, urinary tract infection, loss in renal function, or, possibly, sepsis or death



Urinary upper tract obstruction syndrome 1

Symptoms are typified by the symptoms of ureteral stricture or ureteral or renal stone

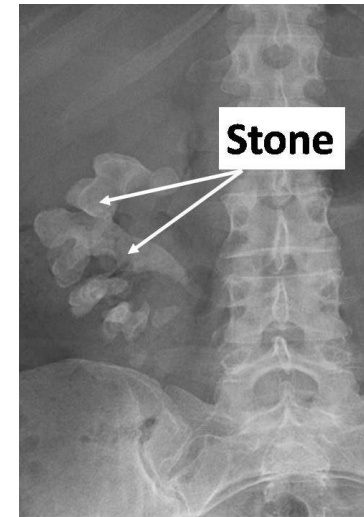The principal complaints are pain in the flank radiating along the course of the ureter, gross total hematuria, gastrointestinal symptoms, chills, fever, burning on urination, and cloudy urine with onset of infection, which is the common consequence of obstruction or vesicoureteral reflux



Urinary upper tract obstruction syndrome 2

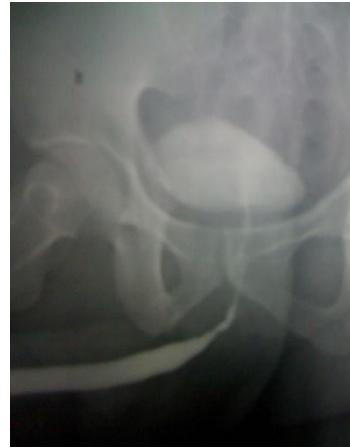Nausea, vomiting, loss of weight and strength, and pallor are due to uremia secondary to bilateral hydronephrosis
Anemia, leukocytosis, microscopic hematuria

Ureter: in the early stages intravesical pressure is normal; later added stretch effect at the lower end of the ureter induces further hydroureteronephrosis; finally the ureteral wall becomes attenuated



Urinary mid tract obstruction syndrome 1

Typified by the symptoms of urethral stricture, benign prostatic hyperplasia, neurogenic bladder, and tumor of the bladder involving the vesical neck

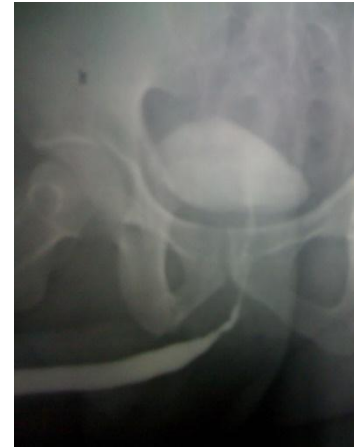

Symptoms: hesitancy in starting urination, lessened force and size of the stream, and terminal dribbling; hematuria, which may be partial; cloudy urine (due to complicating infection), acute urinary retention; anemia, leukocytosis, microscopic hematuria

Urinary mid tract obstruction syndrome 2

Stages

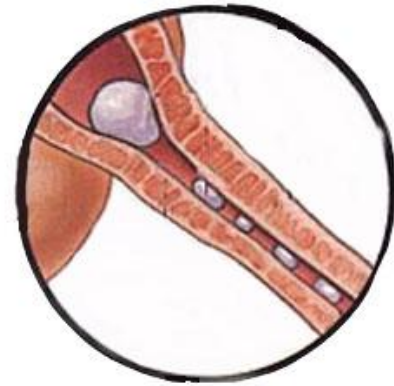
- compensation - the bladder musculature becomes hypertrophied → the thickness may double or triple, hypertrophied muscle may be seen endoscopically → superimposed with secondary infection
- decompensation - large obstructing gland can be palpated rectally and observed cystoscopically, may appears as a mild obstruction cystoscopically



Urinary lower tract obstruction syndrome 1

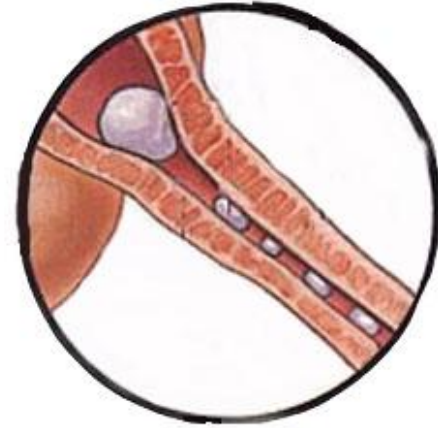
The principal symptoms are hesitancy in starting urination, lessened force and size of the stream, and terminal dribbling; hematuria, which may be partial, initially, with stricture or total with prostatic obstruction or vesical tumor, cloudy urine (due to complicating infection), acute urinary retention

Anemia, leukocytosis, microscopic hematuria



Urinary lower tract obstruction syndrome 2

Obstruction → Hydrostatic pressure proximal → dilation of the urethra → The wall of the urethra become thin → form of diverticulum → Infected urine + urinary extravasation → periurethral abscess



Typified by the symptoms of urethral stricture, benign prostatic hyperplasia, neurogenic bladder, and tumor of the bladder involving the vesical neck.

Urinary tract obstruction syndrome

USMLE test 1

- (M1.RL.18) A 45-year-old man presents with a 3-day history of right-sided flank pain due to a lodged ureteral stone. What changes would be expected to be seen at the level of glomerular filtration?
- 1. Increase in glomerular capillary oncotic pressure, 2. Increase in Bowman's space capillary oncotic pressure, 3. Increase in Bowman's space hydrostatic pressure, 4. Increase in filtration fraction, 5. No change in filtration fraction

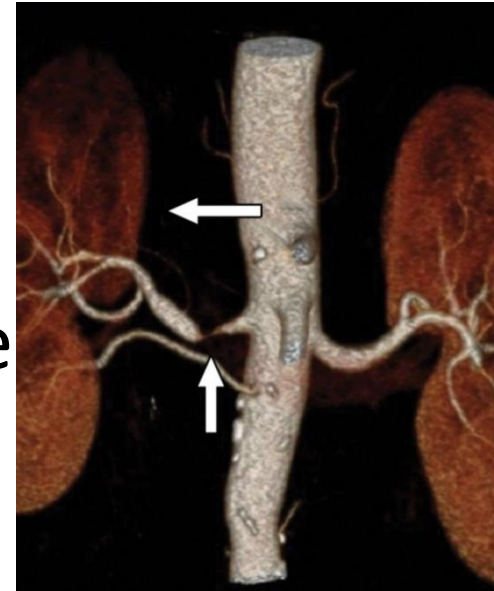
Urinary tract obstruction syndrome

USMLE test 2

- (M1.RL.78) A 72-year-old male presents to his primary care physician with urinary hesitancy and urinary dribbling that began 6 weeks ago and has gradually worsened. Rectal exam reveals a markedly enlarged prostate. CT scan demonstrates dilated ureters and renal pelvises. Which of the following likely accounts for the CT scan results
- 1. Urethral obstruction, 2. Autosomal dominant polycystic kidney disease, 3. Prerenal azotemia, 4. Elevated serum PSA, 5. Multiple endocrine neoplasia type 1

Hypertensive syndrome 1

- elevated $\geq 140/90$ mm Hg blood pressure (renal or renovascular hypertension), caused by a narrowing in the arteries that deliver blood to the kidney (renal artery stenosis)
- when the kidneys receive low blood flow, they respond by releasing hormones that stimulate the body to retain sodium and water, blood vessels fill with additional fluid, and blood pressure increases



Hypertensive syndrome 2

- the narrowing in one or both renal arteries is most often caused by atherosclerosis, or hardening of the arteries
- symptoms: headache, confusion, blurred or double vision, bloody (pink-colored) urine, nosebleed, bruits over affected renal artery
- hypertension can cause chronic kidney disease.

