V.N. KARAZIN KHARKIV NATIONAL UNIVERSITY
School of Medicine

Management of patient with back pain

associate professor of internal medicine department, PhD, MD Makharynska O.S

Lumbar spine anatomy

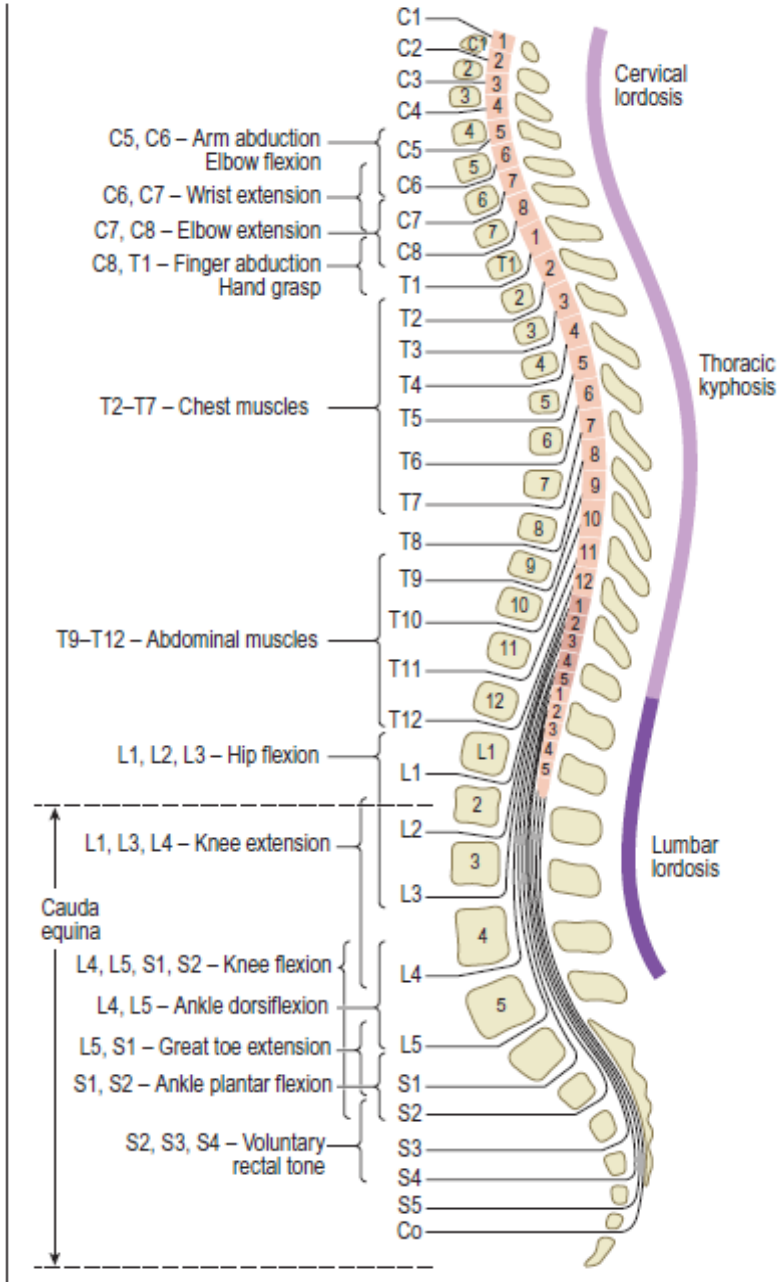

The spine is divided into the cervical, thoracic, lumbar and sacral segments. Most spinal diseases affect multiple segments, causing alteration in the posture or function of the whole spine. Spinal disease may occur without local symptoms and present with pain, neurological symptoms or signs in the trunk or limbs.

Lumbar spine: the surface markings are the spinous processes of L4/5, which are level with the pelvic brim, and the ‘dimples of Venus’, which overlie the sacroiliac joints. The normal lordosis may be lost in disorders such as ankylosing spondylitis and lumbar disc protrusion.

The principal movements are flexion, extension, lateral flexion and rotation. Most patients can bring the tips of their fingers at least to the level of the knees in forward and lateral flexion. Extension should be approximately 10–20°. In flexion, the upper segments move first, followed by the lower segments, to produce a smooth lumbar curve. However, even with a rigid lumbar spine, patients may be able to touch their toes if their hips are mobile.

In the adult, the spinal cord ends at L2. Below this, the spinal nerve roots may be injured or compressed by disc protrusion. Above this level the spinal cord itself may be involved.

Macleod's Clinical Examination
Thirteenth edition 2013

ICD-10CM # M54.89 Back pain. Other Dorsalgia

M54.9 Dorsalgia,
Unspecified
M54.5 Low Back Pain
F45.42 Pain Disorder with Related Psychological Factors
M54.08 Panniculitis
Affecting Regions of Neck and Back, Sacral and Sacrococcygeal Region
S23.9XXA Sprain of Unspecified Parts of Thorax, Initial Encounter
M43.27 Fusion of Spine,
Lumbosacral Region
M43.28 Fusion of Spine,
Sacral and Sacrococcygeal Region
M53.2X7 Spinal Instabilities,
Lumbosacral Region
M53.3 Sacrococcygeal
Disorders, Not Elsewhere Classified

Trauma: injury to bone, joint, or ligament.
Mechanical: pregnancy, obesity, fatigue, scoliosis.
Degenerative: osteoarthritis.
Infections: osteomyelitis, subarachnoid or spinal abscess, TB, meningitis, basilar pneumonia.
Metabolic: osteoporosis, osteomalacia.
Vascular: leaking aortic aneurysm, subarachnoid or spinal hemorrhage/infarction.
Neoplastic: myeloma, Hodgkin's disease, carcinoma of pancreas, metastatic neoplasm from breast, prostate, lung.
GI: penetrating ulcer, pancreatitis, cholelithiasis, inflammatory bowel disease.
Renal: hydronephrosis, calculus, neoplasm, renal infarction, pyelonephritis.
Hematologic: sickle cell crisis, acute hemolysis.
Gynecologic: neoplasm of uterus or ovary, dysmenorrhea, salpingitis, uterine prolapse.
Inflammatory: ankylosing spondylitis, psoriatic arthritis, Reiter's syndrome (reactive arthritis). Lumbosacral strain.
Psychogenic: malingering, hysteria, anxiety.
Endocrine: adrenal hemorrhage or infarction.

History

While it may not be possible to define a precise cause of back pain symptoms for most patients, it is important to evaluate for evidence of specific etiologies of back pain. The history should include location, duration, and severity of the pain, details of any prior back pain, and how current symptoms compare with any previous back pain. The medical history should focus on both triggering and alleviating factors, as well as on the character of the pain.

We also ask about constitutional symptoms (eg, unintentional weight loss or night sweats), history of malignancy, precipitants or precipitating events, therapies attempted, neurologic symptoms (eg, weakness, falls or gait instability, numbness or other sensory changes, or bowel/bladder symptoms), stability or progression of symptoms, history of recent bacterial infections (particularly bacteremia), recent history or current use of injection drugs, history or current use of corticosteroid medications, and recent history of procedures in the back.

Patients should also be evaluated for social or psychologic distress that may be contributing. Potentially useful items are a history of failed previous treatments, substance abuse, and disability compensation. Screening for depression may be helpful.

Features that may suggest underlying systemic disease include history of cancer, age >50 years, unexplained weight loss, duration of pain >1 month, nighttime pain, and unresponsiveness to previous therapies. Injection drug use, recent bacterial infection (particularly bacteremia), or fever increase the suspicion of spinal infection.

Pain from entrapment of the sciatic nerve is called sciatica. Patients with sciatica describe pain, burning sensation, or aching in the buttocks radiating down the posterior thigh to the posterolateral aspect of the calf. Pain is worsened by sneezing, laughing, or straining at stool. One of the tests for sciatica is the straight leg raising test. The patient is asked to lie supine while the examiner flexes the extended leg to the trunk at the hip. The presence of pain is a positive test result. The patient is asked to plantarflex and dorsiflex the foot. This stretches the sciatic nerve even more.

http://cursoenarm.net/UPTODATE/contents/mobipreview.htm?39/36/40512

THE PHYSICAL EXAMINATION

Physical examination — In general, the purpose of the physical examination is to identify features that suggest that further evaluation is indicated, rather than to make a primary diagnosis. The physical examination should include the following components:

●**Inspection of back and posture** – Inspection of the patient on physical examination can reveal anatomic abnormalities such as scoliosis or hyperkyphosis, commonly known as the "dowager's hump."

●**Palpation/percussion of the spine** – Palpation and/or percussion of the back is usually performed to assess vertebral or soft tissue tenderness. Vertebral tenderness is a sensitive, but not specific, finding for spinal infection, and may also be seen in patients with vertebral metastases and osteoporotic compression fracture .

●**Neurologic exam** – Patients should have a neurologic exam including evaluation of the reflexes, strength, sensation, and gait. For patients suspected of having a radiculopathy, neurologic testing should focus on the L5 and S1 nerve roots, since most clinically significant radiculopathies occur at these levels

●**Straight leg raising** – The straight leg raise and other maneuvers can be helpful in identifying whether symptoms are radicular in nature. These are described separately (see ***Root compression tests***).

●**Nonorganic signs (Waddell's signs)** – Patients with psychologic distress that is contributing to back pain symptoms may have associated inappropriate physical signs, also known as "Waddell's signs". These include patient overreaction during physical examination, superficial tenderness, straight leg raise that improves when the patient is distracted, unexplainable neurological deficits (eg, nondermatomal distribution of sensory loss, sudden giving way or jerky movements with motor exam, inconsistency in observed spontaneous activity [dressing, getting off table]), and pain elicited by axial loading (pressing down on top of head, or rotating the body at hips or shoulders). The presence of multiple Waddell's signs suggests a psychologic component to a patient's pain, although they do not seem to be useful for predicting the ability to return to work or success of rehabilitation.

●**Other** – For patients with new or worsening urinary incontinence, we measure bladder post void residual (eg, by ultrasound) to differentiate overflow incontinence from urge and/or stress incontinence. If a patient's history strongly suggests malignancy, we evaluate as appropriate (eg, lymph node exam, breast exam, prostate evaluation). Other physical examination components (eg, hip examination or examination for peripheral vascular disease) should be performed based on the history.

Chart 2. *Wadell's non-organic signs for low back pain.*
1. Sensitivity: Pain on light palpation in the lumbar region, Pain on disseminated palpation not corresponding to anatomical pattern
2. Simulation: Pain on axial cranial compression, Pain on shoulder rotation
3. Distraction: Difference when raising leg in seated or supine position
4. Regional: Motor or sensitive abnormalities that cannot be explained on an anatomical basis
5. Sign of hyper-reaction: Verbalization or expression disproportionate to symptoms.

Waddell's signs

CATEGORY	SIGNS
Tenderness	*Superficial:* light pinching causing pain = positive *Nonanatomic:* deep tenderness over a wide area = positive
Simulation	*Axial loading:* downward pressure on the head causing low back pain = positive *Rotation:* Examiner holds shoulders and hips in same plane and rotates patient. Pain = positive
Distraction	Straight leg raise causes pain when formally tested, but straightening the leg with hip flexed ninety degrees to check Babinski does not
Regional	*Weakness:* multiple muscles not enervated by the same root *Sensation:* glove and stocking loss of sensation.
Overreaction	Excessive show of emotion

http://www.uptodate.com/contents/evaluation-of-low-back-pain-in-adults?source=see_link#H4660047459

THE PHYSICAL EXAMINATION

Examination sequence

Ask the patient to stand with the back fully exposed.

Look

- Look for obvious deformity, such as decreased/increased lordosis, obvious scoliosis, soft-tissue abnormalities like a hairy patch or lipoma that might overlie a congenital abnormality, e.g. spina bifida.

Feel

- Palpate the spinous processes and paraspinal tissues. Note the overall alignment and focal tenderness (the L4/5 interspinous space is palpable at the level of the iliac crests).
- After warning the patient, lightly percuss the spine with your closed fist and note any tenderness.

Move

- Flexion: ask the patient to try to touch his toes with his legs straight. Record how far down his legs he can reach. Some of this movement depends on hip flexion. Usually the upper segments flex before the lower ones, and this progression should be smooth.
- Extension: ask the patient to straighten up and lean back as far as possible (normal 10–20° from neutral erect posture).
- Lateral flexion: ask him to reach down to each side, touching the outside of the leg as far down as possible while keeping the legs straight

A detailed neurologic examination is essential in all patients presenting with back pain, spine deformity, or traumatic spine injury.

Diagnostic Workup

Imaging is not warranted for most patients with acute low back pain. Without signs and symptoms indicating a serious underlying condition, imaging does not improve clinical outcomes in these patients. Even with a few weaker red flags, four to six weeks of treatment is appropriate before consideration of imaging studies. If a serious condition is suspected, magnetic resonance imaging (MRI) is usually most appropriate. Computed tomography is an alternative if MRI is contraindicated or unavailable. Clinical correlation of MRI or computed tomography findings is essential because the likelihood of false-positive results increases with age. Radiography may be helpful to screen for serious conditions, but usually has little diagnostic value because of its low sensitivity and specificity.

Laboratory tests such as complete blood count with differential, erythrocyte sedimentation rate, and C-reactive protein level may be beneficial if infection or bone marrow neoplasm is suspected. These tests may be most sensitive in cases of spinal infection because lack of fever and a normal complete blood count are common in patients with spinal infection. Because laboratory testing lacks specificity, MRI with and without contrast media and, in many cases, biopsy are essential for accurate diagnosis

http://www.aafp.org/afp/2012/0215/p343.html

THE PHYSICAL EXAMINATION

REGIONAL EXAMINATION OF THE MUSCULOSKELETAL SYSTEM—HEAD, SPINE, AND PELVIS—cont'd

Lumbar spine

Look	Look for a normal lordosis or any scoliosis. Look for any asymmetry of the pelvic brim or the crease of the buttocks.
Feel	Percuss the vertebrae for tenderness. Palpate the paraspinal muscles for spasm or tenderness.
Move	While standing in an erect posture, bend forward as though trying to touch the toes, bend backward to arch the back, and bend from side to side. The person may be able to place the hands flat on the ground if hypermobile. Flexion can be more formally assessed with the Schober test by measuring extension of a line drawn when upright between 10 cm above and 5 cm below the level of the posterior iliac spines as identified by the dimples of Venus.
Stress	Tests for tension of the lumbar roots should be performed when patient is lying down. *Femoral nerve stretch test:* With the person lying prone, hold the ankle and passively flex the knee as far as it will go. The test is positive if pain is felt in the isolateral anterior aspect of the thigh. *Sciatic nerve stretch test:* With the person lying supine, gently raise the straight leg to the maximum angle achievable without significant pain and then dorsiflex the ankle. An increase in pain indicates sciatic nerve root tension.
Tests	The lumbar spine houses the lumbar spinal nerve roots, and neurologic symptoms and signs should be elicited.

Lumbar flexion.

Lumbar extension.

Left lateral flexion.

Right lateral flexion.

Rheumatology 6th Ed [2015]

THE PHYSICAL EXAMINATION

Measuring kyphosis — If hyperkyphosis is suspected, objective measurement of kyphosis should be performed to diagnose and determine severity of hyperkyphosis. The degree of kyphosis can be measured clinically or radiographically.

Clinical methods use devices such as the flexicurve ruler, goniometer, inclinometer, or Debrunner kyphometer (in which a protractor is applied to the upper back). Other clinical measures of kyphosis include: the distance from the occiput-to-wall, the number of 1.7 cm blocks between the head and exam table while lying flat with the neck in a neutral position, and qualitative visual measures.

The radiologic methods generally use lateral spine radiographs with either manual or computer-assisted calculation of an angle of curvature, termed the Cobb angle. The Cobb angle is measured by drawing perpendicular lines from two lines: (1) a line from the upper border of the vertebral body marking the beginning of the thoracic curve (commonly T4); and (2) a line from the inferior border of the vertebral body representing the interface between the thoracic-lumbar curves (commonly T12). The Cobb angle is then calculated as the angle of intersection of these perpendicular lines. Although the Cobb angle was first developed to assess scoliosis angles on spinal radiographs, it was later modified to measure kyphosis and is currently considered by some to be the gold standard of kyphosis measurement.

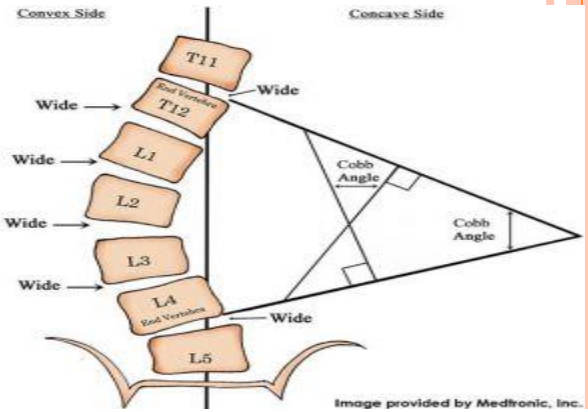

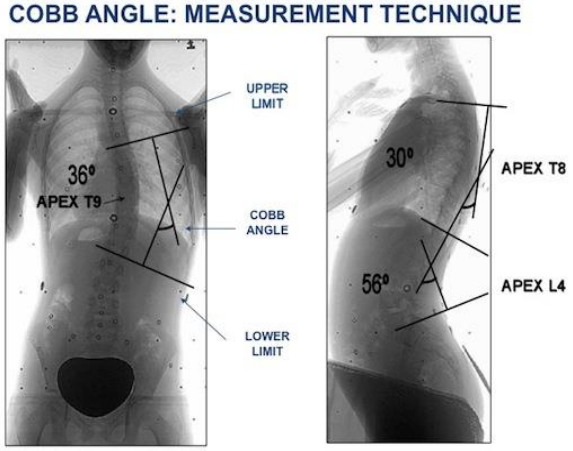

Physical examination for scoliosis mainly_consists of the Adam's forward bend test. The patient stands and bends forward at the waist, with the examiner assessing for symmetry of the back from behind and beside the patient. Patients with possible scoliosis will have a lateral bending of the spine, but the curve will cause spinal rotation and eventually a rib hump, which is visible on examination. The examiner may then attempt to quantify the spinal curve and rotation with a scoliometer, or inclinometer. The inclination angle measured by a scoliometer will help determine which patients may need radiography. The estimated magnitude of the spinal curve can be used to determine the angle of trunk rotation. This can help avoid imaging in patients with clearly insignificant curves; however, a Cobb angle measurement using radiography is needed for the official diagnosis of scoliosis (Tangential lines are drawn from the superior end plate of the superior vertebra and the inferior end plate of the inferior vertebra. The angle formed at the intersection of these two lines is the Cobb angle. A Cobb angle of at least 10 degrees is necessary for diagnosing scoliosis.).

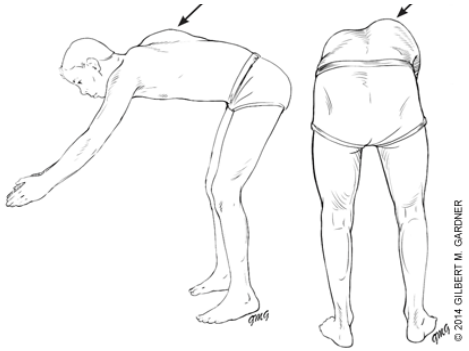

http://cursoenarm.net/UPTODATE/contents/mobipreview.htm?39/36/40512

THE PHYSICAL EXAMINATION

Schober's test for forward flexion

- Mark the skin in the midline at the level of the posterior iliac spines (L5), which overlie the sacroiliac joints (Fig. 14.24; mark A).
- Use a tape measure to draw two more marks: one 10 cm above (mark B) and one 5 cm below this (mark C).
- Place the end of the tape measure on the upper mark (B). Ask the patient to touch his toes. The distance from mark B to mark C should increase from 15 to more than 20 cm.

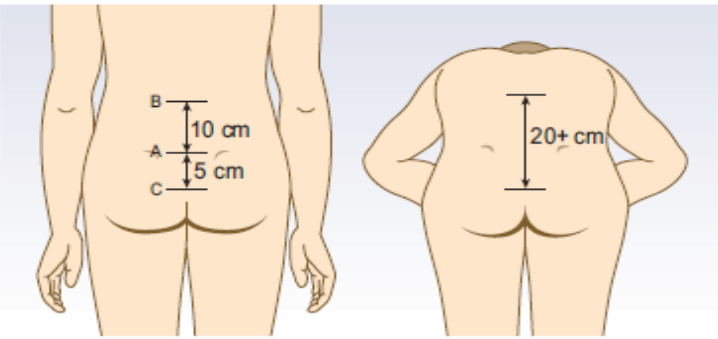

Schober's test. Measuring forward flexion of the spine.

Technique for evaluating motion of the lumbar spine. *A*, Test for extension of the spine. *B*, Test for rotation of the spine.

Flip test for functional overlay

Examination sequence

- Ask the patient to sit on the end of the couch with the hips and knees flexed to 90°
- Examine the knee reflexes.
- Extend the knee, as if to examine the ankle jerk. A patient with nerve root impingement will lie back 'flip'

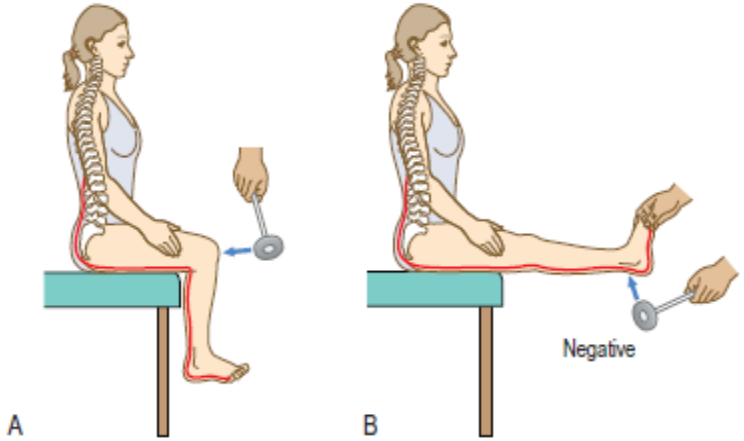

Sciatic nerve. The 'flip' test. **(A)** Divert the patient's attention to the tendon reflexes. **(B)** The patient with physical nerve root compression cannot permit full extension of the leg.

Macleod's Clinical Examination
Thirteenth edition 2013

Neurologic examination

Rheumatology 6th Ed [2015]

Upper motor neuron and peripheral nerve abnormalities may also cause neurologic dysfunction. Muscle spasticity, hyperreflexia, and the Babinski and Hoffman signs develop in patients with upper motor neuron dysfunction. Distinction among upper motor neuron, nerve root, and peripheral nerve lesions is essential for the differential diagnosis of back pain.

Sensory examination

Sensory findings are less reliable than reflex or strength-testing findings. A given area of skin also receives innervation from two dermatomes, thus making sensory testing less specific for defining the affected nerve root. However, if a peripheral nerve is injured, a specific muscle may become paralyzed or specific skin areas may become anesthetic.

Deep tendon reflexes

Testing the deep tendon reflexes, especially the patellar reflex (L4) and Achilles reflex (S1), can be useful. However, no reliable reflex is available to test for L5. Older individuals may lose reflex function, particularly at the Achilles (which is likely to be symmetric), and previous episodes of nerve compression may have caused a loss of reflexes that may not return even with recovery of motor and sensory function. Excessively brisk reflexes can be indicative of an upper motor neuron process such as cervical myelopathy.

Provocative maneuvers

The hip joints should be moved through their range of motion. Differentiation of hip pain from sacroiliac joint pain may be determined with the Patrick or "FABER" (flexion, abduction, external rotation) test. A Patrick maneuver producing low back pain suggests sacroiliac joint pain but can be nonspecific and is seen with spondylolisthesis, spinal stenosis, facet syndrome, and acute discogenic pain secondary to an annular tear. A Patrick maneuver producing groin or anterior thigh discomfort suggests hip disease.

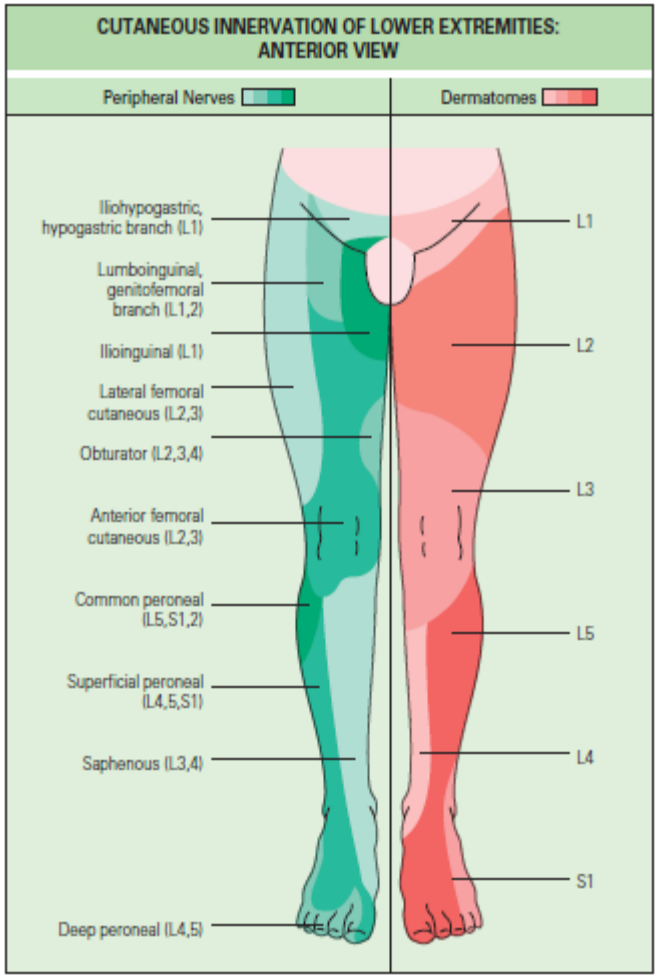

Root tension signs

The straight leg–raising test detects irritation of the sciatic nerve (L5, S1). Passive raising of the leg with the knee extended stretches the sciatic nerve and its nerve roots and dural attachments. When the spinal nerve is inflamed and stretched, the patient will experience pain along its anatomic course. The pain associated with nerve root irritation is maximal between 20 and 70 degrees of elevation. Symptoms occurring at greater than 70 degrees of elevation may simply be related to mechanical pain secondary to muscle or ligamentous strain or joint disease.25 Pain may also be experienced in the leg below the knee when the contralateral normal leg is raised, a finding known as the crossed straight leg raise. The crossed straight leg–raising test is insensitive but highly specific

Rheumatology 6th Ed [2015]

THE PHYSICAL EXAMINATION

Neurologic examination of the lower extremities includes strength, sensation, and reflex testing *(pics below)*, even in the absence of significant sciatica. A straight leg raise test is positive for L4-S1 nerve root pain if it radiates below the knee. A reverse straight leg raise test (extending hip and flexing knee while in the prone position) is positive for L3 nerve root pain if it radiates into the anterior thigh. A central, paracentral, or lateral disk herniation may affect different nerve roots at the same level.

Macleod's Clinical Examination
Thirteenth edition 2013

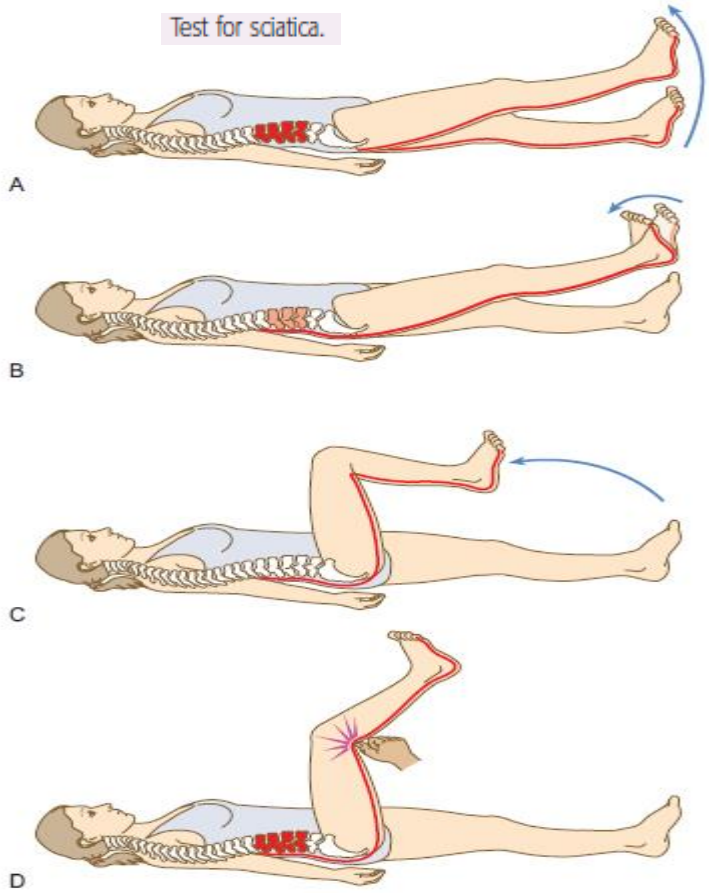

Stretch tests: sciatic nerve. (A) Straight-leg raising limited by tension of root over prolapsed disc. **(B)** Tension increased by dorsiflexion of foot (Bragard's test). **(C)** Root tension relieved by flexion at the knee. **(D)** Pressure over centre of popliteal fossa bears on posterior tibial nerve, which is 'bowstringing' across the fossa, causing pain locally and radiation into the back.

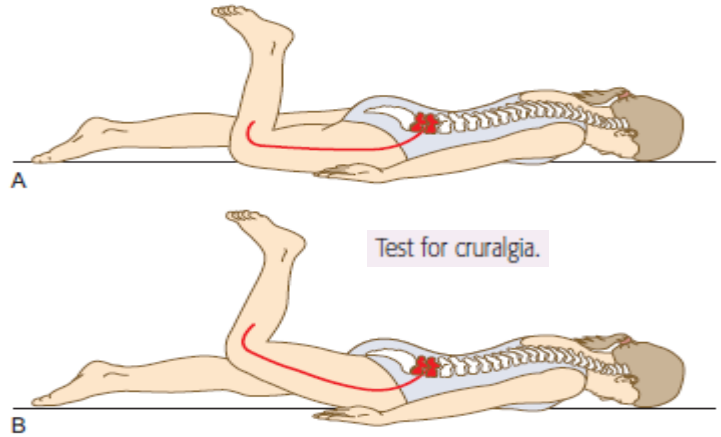

Stretch test: femoral nerve. (A) Pain may be triggered by knee flexion alone. **(B)** Pain may be triggered by knee flexion in combination with hip extension.

Root compression tests

Intervertebral disc prolapse causing nerve root pressure occurs most often in the lower lumbar region, leading to compression of the corresponding nerve roots.

The femoral nerve (L2–4) lies anterior to the pubic ramus, so straight-leg raising or other forms of hip flexion do not increase its root tension. Problems with the femoral nerve roots may cause quadriceps weakness and/or diminished knee jerk on that side.

The sciatic nerve (L4–5; S1–3) runs behind the pelvis, so manoeuvres to put tension on the lower nerve roots (L4 exiting the L4/5 foramen, L5 exiting the L5/S1 foramen) differ from those for the upper lumbar nerve roots (L2, L3).

Straight-leg raise tests L4, L5, S1 nerve root tension (L3/4, L4/5 and L5/S1 disc prolapse respectively).

THE PHYSICAL EXAMINATION

Red flags are often used to distinguish a common, benign episode from a more significant problem that requires urgent workup and treatment

'Red flag' and 'yellow flag' features for acute low back pain

'Red flag' features

Red flags are features that may indicate serious pathology and require urgent referral

History

- Age <20 years or >55 years
- Recent significant trauma (fracture)
- Pain:
  - Thoracic (dissecting aneurysm)
  - Non-mechanical (infection/tumour/ pathological fracture)
- Fever (infection)
- Difficulty in micturition
- Faecal incontinence
- Motor weakness
- Sensory changes in the perineum (saddle anaesthesia)
- Sexual dysfunction, e.g. erectile/ejaculatory failure
- Gait change (cauda equina syndrome)
- Bilateral 'sciatica'

Past medical history

- Cancer (metastases)
- Previous steroid use (osteoporotic collapse)

System review

- Weight loss/malaise without obvious cause, e.g. cancer

'Yellow flag' features

These are psychosocial factors associated with greater likelihood of long-term chronicity and disability

- A history of anxiety, depression, chronic pain, irritable bowel syndrome, chronic fatigue, social withdrawal
- A belief that the diagnosis is severe, e.g. cancer. Faulty beliefs can lead to 'catastrophisation' and avoidance of activity
- Lack of belief that the patient can improve leads to an expectation that only passive, rather than active, treatment will be effective
- Ongoing litigation or compensation claims, e.g. work, road traffic accident

Red Flags for Serious Etiologies of Acute Low Back Pain

POSSIBLE ETIOLOGY	*HISTORY FINDINGS*	*PHYSICAL EXAMINATION FINDINGS*
Cancer	Strong: Cancer metastatic to bone Intermediate: Unexplained weight loss Weak: Cancer, pain increased or unrelieved by rest	Weak: Vertebral tenderness, limited spine range of motion
Cauda equina syndrome	Strong: Bladder or bowel incontinence, urinary retention, progressive motor or sensory loss	Strong: Major motor weakness or sensory deficit, loss of anal sphincter tone, saddle anesthesia Weak: Limited spine range of motion
Fracture	Strong: Significant trauma related to age* Intermediate: Prolonged use of steroids Weak: Age older than 70 years, history of osteoporosis	Weak: Vertebral tenderness, limited spine range of motion
Infection	Strong: Severe pain and lumbar spine surgery within the past year Intermediate: Intravenous drug use, immunosuppression, severe pain and distant lumbar spine surgery Weak: Pain increased or unrelieved by rest	Strong: Fever, urinary tract infection, wound in spine region Weak: Vertebral tenderness, limited spine range of motion

Macleod's Clinical Examination
Thirteenth edition 2013

IMAGING

The majority of patients with low back pain of less than four weeks duration do not require imaging. Earlier use of imaging for low back pain without associated symptoms is not associated with improved outcomes but increases the use of invasive procedures.

Plain radiographs

The Quebec Task Force on Spinal Disorders suggested that in patients without neurologic dysfunction, plain radiographs should not be obtained during the first week of an acute episode of back pain. congenital abnormalities, including spina bifida, transitional vertebrae, Schmorl nodes, and mild scoliosis, are only rarely causes of back pain. When lumbar radiographs are obtained, a single lateral film offers the view with the highest yield in detecting vertebral compression fractures. Others have suggested that anteroposterior and lateral views are adequate for evaluation. The anteroposterior and lateral views demonstrate the scoliotic curvature and sagittal balance, which can often help specialists in interpreting the biomechanics of the spine. Flexion and extension views can demonstrate segmental instability, a potential cause of unexplained back and radicular symptoms. Clinical practice guidelines have recommended that the criteria for obtaining plain films include older age, recent significant trauma, history of prolonged steroid use, previous cancer, recent infection, fever, intravenous drug abuse, unexplained weight loss, or pain with recumbency.

Radionuclide bone scintigraphy

Technetium-99m diphosphonate scans are useful in assessing for infection, tumors, inflammatory arthritis, and fractures. The sensitivity of bone scanning is generally equal to that of MRI (90% vs. 96%), but it is less specific, for example, in detecting vertebral osteomyelitis. Bone scintigraphy is better than MRI when evaluation of the whole skeleton is required, such as in patients with metastatic disease who may have unsuspected bone lesions in other parts of the skeleton.

Computed tomography

CT is the best technique for assessing the bony architecture of the spinal column, including the sacroiliac joints, before changes are noted on plain radiographs. In addition, the structural relationships of soft tissues (ligaments, nerve roots, fat, intervertebral disks) can be evaluated as they relate to their bony environment. CT is an excellent technique for identifying mechanical disorders, including spinal stenosis, spondylosis, spondylolysis, spondylolisthesis, trauma, congenital anomalies, and fractures. CT can visualize cortical bone destruction, calcified tumor matrix, and soft tissue extension of tumors affecting the spine and is superior to MRI in this regard.

Magnetic resonance imaging

MRI has become the imaging modality of choice to evaluate lumbar spine disorders. Patients who are not candidates for MRI evaluation include those on life support systems and those who have a cardiac pacemaker or ferromagnetic clips in the abdomen or brain or on blood vessels. MRI is an excellent technique to view the spinal cord. It identifies syringomyelia, atrophy, cord infarction, cord injury, multiple sclerosis, intramedullary tumors, and hematoma. Use of contrast media (gadopentetate dimeglumine) for MRI improves the characterization of spinal cord tumors.

Rheumatology 6th Ed [2015]

ELECTRODIAGNOSTIC STUDIES

Electrodiagnostic studies can confirm the clinical suspicion of nerve root compression, define the distribution and severity of involvement, and document or exclude other disorders of nerves or muscles that can contribute to the patient's symptoms and signs. This tool is most helpful in cases in which peripheral entrapment, plexitis, anterior horn cell disease, or myopathy may be present. Electrodiagnostic tests can be helpful in identifying neurophysiologic abnormalities in patients in whom clinical examination (pain radiation, sensory changes, muscular weakness) does not necessarily indicate nerve root dysfunction. Neurophysiologic tests can also document normal function in cases in which radiographic techniques have revealed anatomic abnormalities.

Electromyography

Electromyography (EMG) is the most sensitive tool for the diagnosis of radiculopathy. EMG measures the action potentials of muscle fibers. As the nerve supplying a muscle becomes compressed, fibers to that muscle are lost and eventually replaced with regenerated fibers. This process of denervation and reinnervation occurs over time. EMG may not be able to document abnormalities until 3 to 4 weeks after the initial insult. A negative finding on EMG does not invalidate a patient's pain and sensory complaints but does make complaints of weakness and motor deficit much less likely to be based on spinal nerve injury.

Nerve conduction tests

In contrast to EMG, nerve conduction test results become abnormal as soon as nerve damage occurs. Nerve conduction tests include evaluation of conduction velocity and amplitude along a segment of a peripheral nerve. They are helpful in distinguishing peripheral entrapment and neuropathy from radiculopathy. Changes on EMG may recede with resolution of the nerve impingement. However, patients in whom operative decompression provides relief of symptoms may have persistent abnormalities on EMG 1 year after surgery.

Lumbar diskography is a procedure associated with the injection of contrast material through a percutaneous needle into the nucleus pulposus suspected of causing the back pain. Reproduction of the patient's pain is considered a positive test. The test is used for patients with a degenerative disk who may be considered for spinal fusion, disk replacement, or intradiscal therapy because of persistent pain. Its clinical significance remains controversial

CLINICAL LABORATORY TESTS

Patients with constitutional symptoms or who have failed conservative therapy may benefit from laboratory evaluation to exclude systemic processes such as infection, neoplasia, or visceral disease. The most useful tests in helping differentiate medical from mechanical low back pain is measurement of the erythrocyte sedimentation rate or C-reactive protein level, which can suggest the presence of systemic inflammation. Abnormalities in the complete blood count (hematocrit, leukocyte count, or platelet count) may be indicative of an inflammatory disorder, including neoplasms. Alterations in calcium concentration and alkaline phosphatase activity suggest diffuse bone disease (e.g., Paget disease, metastases). Elevated acid phosphatase activity may mirror the extent of metastases from prostatic cancer. Urinalysis can identify individuals with renal abnormalities (nephrolithiasis). Detection of occult blood in stool is a screening test for ulcers or gastrointestinal tumors.

Rheumatology 6th Ed [2015]

ACUTE BACK PAIN

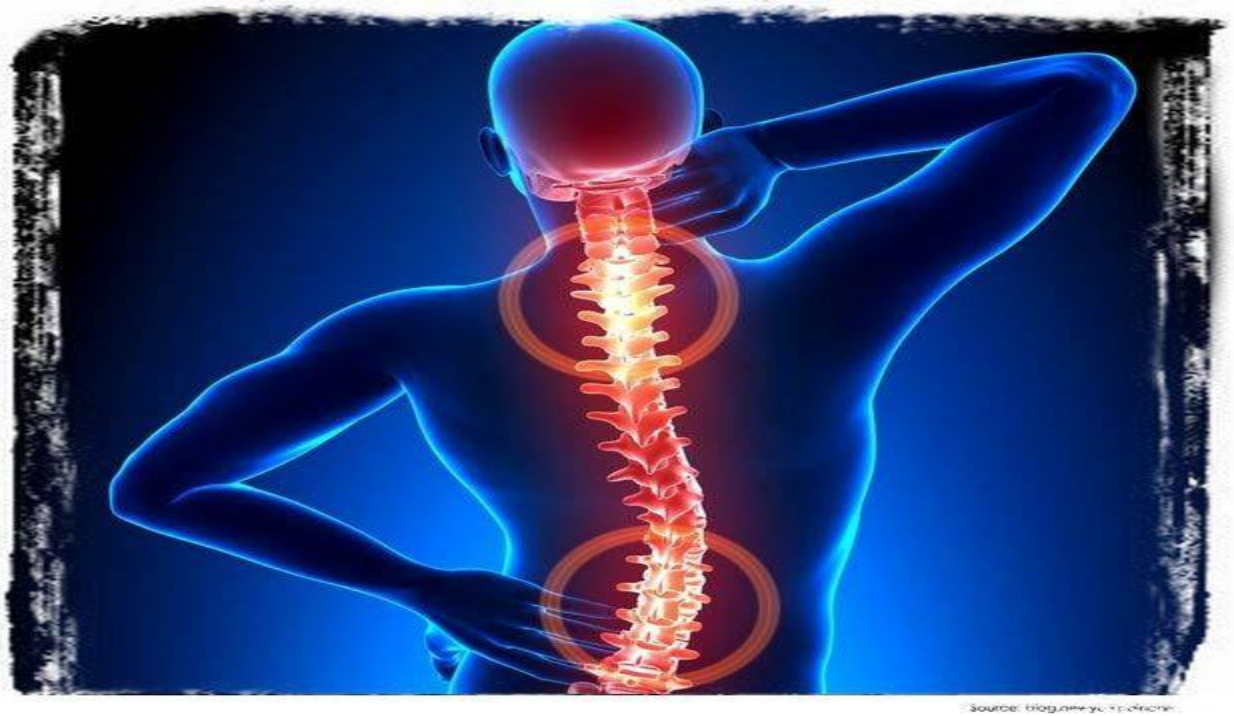

DIFFERENTIAL CONSIDERATIONS IN ACUTE LOW BACK PAIN

Emergent

Aortic dissection.
Cauda equina syndrome.
Epidural abscess or hematoma.
Meningitis.
Ruptured/expanding aortic aneurysm.
Spinal fracture or subluxation with cord or root impingement.

Urgent

Back pain with neurologic deficits.
Disk herniation causing neurologic compromise.
Malignancy.
Sciatica with motor nerve root compression.
Spinal fractures without cord impingement.
Spinal stenosis.
Transverse myelitis.
Vertebral osteomyelitis.

Common or Stable

Acute ligamentous injury.
Acute muscle strain.
Ankylosing spondylitis.
Degenerative joint disease.
Intervertebral disk disease without impingement.
Pathologic fracture without impingement.
Seropositive arthritis.
Spondylolisthesis.

Referred or Visceral

Cholecystitis.
Esophageal disease.
Nephrolithiasis.
Ovarian torsion, mass, or tumor.
Pancreatitis.
Peptic ulcer disease.
Pleural effusion.
Pneumonia.
Pulmonary embolism.
Pyelonephritis.
Retroperitoneal hemorrhage or mass.

Emergent acute back pain. Aortic dissection

Clinical manifestations include the following:

Sudden onset of severe chest pain that often has a tearing or ripping quality (classic symptom)

Chest pain may be mild

Anterior chest pain: Anterior chest pain and chest pain that mimics acute myocardial infarction usually are associated with anterior arch or aortic root dissection, typically distinguished from the pain of acute myocardial infarction by its abrupt onset and maximal severity at onset

Neck or jaw pain: Pain in the neck or jaw indicates that the dissection involves the aortic arch and extends into the great vessels.

Tearing or ripping intrascapular pain: May indicate dissection involving the descending aorta

No pain in about 10% of patients

Syncope

Cerebrovascular accident (CVA) symptoms (eg, hemianesthesia, and hemiparesis, hemiplegia), Anxiety and premonitions of death

Altered mental status, Fever

Numbness and tingling, pain, or weakness in the extremities

Horner syndrome (ie, ptosis, miosis, anhidrosis)

Dyspnea, Hemoptysis, Dysphagia

Flank pain (with renal artery involvement)

Abdominal and back pain (with abdominal aorta involvement)

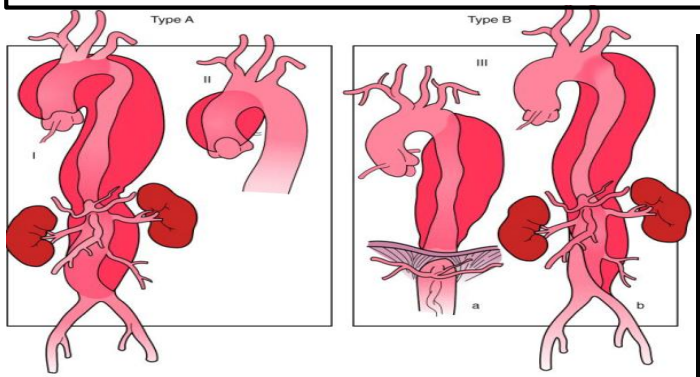

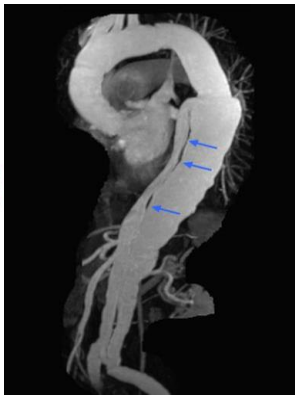

Aortic dissection is defined as separation of the layers within the aortic wall. Tears in the intimal layer result in the propagation of dissection (proximally or distally) secondary to blood entering the intima-media space. Painless dissection (10%) is more common in those with neurologic complications from the dissection and those with Marfan syndrome.

Diagnosis

The diagnosis of acute aortic dissection requires a high index of suspicion and involves the following:

•History and physical examination

•Imaging studies

•Electrocardiography

•Complete blood count, serum chemistry studies, cardiac marker assays

Possible physical examination findings include the following:

•Hypertension

•Hypotension

•Interarm blood pressure differential greater than 20 mm Hg

•Signs of aortic regurgitation (eg, bounding pulses, wide pulse pressure, diastolic murmurs)

•Findings suggestive of cardiac tamponade (eg, muffled heart sounds, hypotension, pulsus paradoxus, jugular venous distention, Kussmaul sign)

•Neurologic deficits (eg, syncope, altered mental status)

•Peripheral paresthesias

•Horner syndrome

•New diastolic murmur

•Asymmetrical pulses (eg, carotid, brachial, femoral)

•Progression or development of bruits

http://emedicine.medscape.com/article/2062452-workup#c10

Emergent acute back pain. Aortic dissection (2)

Imaging studies

•Chest radiography:

Initial imaging technique if it is readily available at the bedside

Widening of the mediastinum is the classic finding

Hemothorax may be evident if the dissection has ruptured, tracheal deviation to the right, esophageal deviation, depression of left mainstem bronchus

•Computed tomography (CT) with contrast:

The definitive test in most patients with suspicion of aortic dissection

Useful only in hemodynamically stable patients

Findings help determine whether hypothermic circulatory arrest is necessary for surgery

•Echocardiography:

Transesophageal echocardiography (TEE) is more accurate than transthoracic echocardiography (TTE), is most useful in ascending aortic dissections, as sensitive and specific as CT and magnetic resonance imaging (MRI),is strongly dependent on operator experience

•MRI:

The most sensitive method for diagnosing aortic dissection

Specificity is similar to that of CT

•Aortography:

Has been the diagnostic criterion standard study for aortic dissection

Is being replaced by newer, safer imaging modalities

•ECG changes can mimic those seen in acute cardiac ischemia

ST-segment elevation can be seen in Stanford type A dissections because the dissection interrupts blood flow to the coronary arteries.

Possible laboratory study findings include the following:

•Leukocytosis: Stress state

•Decreases in hemoglobin and hematocrit values: Leaking or rupture of the dissection

•Elevation of the blood urea nitrogen and creatinine levels: Renal artery involvement or prerenal azotemia

•Elevation of the myocardial muscle creatine kinase isoenzyme, myoglobin, and troponin I and T levels: Myocardial ischemia from coronary artery involvement

•Lactate dehydrogenase elevation: Hemolysis in the false lumen

•Smooth muscle myosin heavy-chain assay: Increased levels in the first 24 hours are 90% sensitive and 97% specific for aortic dissection

•Fibrin degradation product (FDP) elevation: In symptomatic patients, a plasma FDP of 12.6 µg/mL or higher suggests possible aortic dissection with a patent false lumen; an FDP level of 5.6 µg/mL or higher suggests the possibility of dissection with complete thrombosis of the false lumen

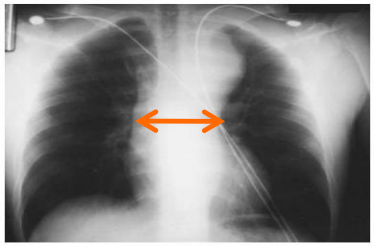

Chest radiograph demonstrating widened mediastinum in a patient with aortic dissection.

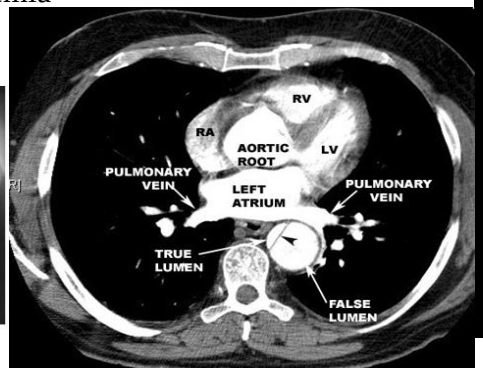

http://emedicine.medscape.com/article/2062452-workup#c10

Cauda Equina Syndrome: *signs and symptoms*

Author:
Yan Yu
Reviewers:
Spencer Montgomery
Owen Stechishin
W. Bradley Jacobs*
** MD at time of publication*

Emergent acute back pain

- Large lumbar degenerative disc herniation (central)
- Severe lumbar spondylosis
- Neoplasm in lumbar spine
- Trauma or epidural hematoma
- Infection (abscess, etc) in lumbar spine

the most common is herniation of the intervertebral disc.

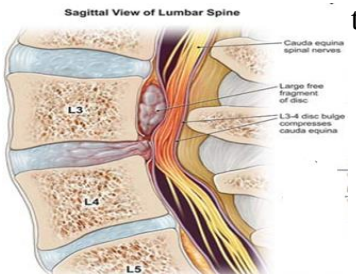

Mechanical compression of sacral (and lumbar) nerve roots between L2 and S1

Cauda Equina Syndrome

Note: ***Surgical Emergency!***

- Goal is to prevent permanent damage to *sacral nerves*, which can happen quickly (within hours) if not treated!
- Pain/sensory disturbance in legs does not have to be bilateral. As soon as bladder/bowel dysfunction is suspected, immediate MRI and surgery!

Damage to motor neurons within the compressed nerve roots

Acutely ↓ stimulation/control of lower limb and perineal (pelvic floor) muscles

(for full mechanisms, see slide on "Signs of lower motor neuron damage")

- **Weakness (flaccid paralysis) in both legs**
- **Areflexia (loss of normal leg reflexes)**

Areflexia of the urinary detrusor and rectal smooth muscle, cannot overcome the residual tone of the internal urethral and anal sphincters

Urinary and fecal retention

Damage to sensory neurons within the compressed nerve roots

Damage to fragile, smaller sacral nerves ↓ sensation in the perineum

Saddle Anesthesia

Pt can't feel when bladder/ bowels are full!

Damage to relatively larger sensory neurons running down both legs

Sensory disturbance in both legs *(numbness, tingling, loss of temperature sensation, etc)*

Mechanically damaged nociceptive sensory neurons send ectopic impulses up to the brain

Neuropathic pain *(shooting, stabbing, lancinating, burning pain radiating down both legs)*

Overflow incontinence

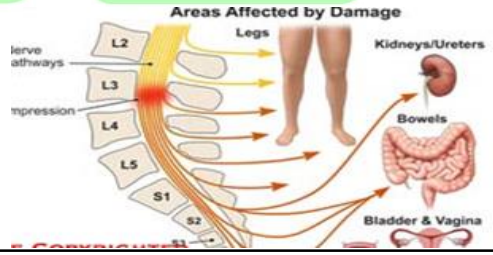

Legend: Pathophysiology | Mechanism | Sign/Symptom/Lab Finding | Complications

Published **November 1st, 2012** on www.thecalgaryguide.com

Emergent acute back pain. Epidural hematoma.

Epidural hematoma

Spinal epidural hematoma may be spontaneous or may follow minor trauma, such as lumbar puncture or epidural anesthesia. Spontaneous spinal epidural hematoma may be associated with anticoagulation, thrombolysis, blood dyscrasias, coagulopathies, thrombocytopenia, neoplasms, or vascular malformations. The peridural venous plexus usually is involved, though arterial sources of hemorrhage also occur. The dorsal aspect of the thoracic or lumbar region is involved most commonly, with expansion limited to a few vertebral levels.

Spinal epidural hematoma typically causes severe localized back pain with delayed radicular radiation that may mimic disk herniation. Associated symptoms may include the following:

- Weakness
- Numbness
- Urinary incontinence
- Fecal incontinence
- Localized back pain

- Weakness (unilateral or bilateral)
- Sensory deficits with radicular paresthesias (unilateral or bilateral)
- Various alterations in reflexes
- Alterations of bladder or anal sphincter tone
- Pain in the both buttock regions and radiating pain to both lower leg

- Myelography outlines the epidural space and may illustrate a space-occupying mass. CT myelography may be used when MRI is unavailable or if the patient cannot tolerate MRI.
- Noncontrast CT scanning of the head not only visualizes skull fractures but also directly images an epidural hematoma. Chronic epidural hematoma may have a heterogeneous appearance due to neovascularization and granulation, with peripheral enhancement on contrast administration.
- Spinal MRI may delineate the location of an epidural hematoma and identify an associated vascular malformation. Spinal cord enhancement may be apparent and should be distinguished from inflammation or neoplasia.
- Complete blood count (CBC) with platelets - To monitor for infection and assess hematocrit and platelets for further hemorrhagic risk.
- Prothrombin time (PT)/activated partial thromboplastin time (aPTT) - To identify bleeding diathesis.
- Serum chemistries, including electrolytes, blood urea nitrogen (BUN), creatinine, and glucose - To characterize metabolic derangements that may complicate clinical course.
- Toxicology screen and serum alcohol level - To identify associated causes of head trauma and establish need for surveillance with regard to withdrawal symptoms.
- Type and hold an appropriate amount of blood - To prepare for necessary transfusions needed because of blood loss or anemia.
- Lumbar puncture provides little additional information and may exacerbate neurologic damage.

http://emedicine.medscape.com/article/1165840-overview#a5

Emergent acute back pain. Epidural abscess.

Ten to thirty percent of spinal epidural abscesses result from direct extension of local infection, usually vertebral osteomyelitis, psoas abscess, or contiguous soft-tissue infection. About half are due to hematogenous seeding (endocarditis, urinary tract infection, respiratory tract infections, intravenous drug use, vascular access devices).
Direct compression of the cord is clearly a major factor. Vascular occlusion due septic thrombophlebitis and/or vasculitis is also a factor. Posteriorly, the epidural space contains fat, small arteries, and the venous plexus. Infections in this space may spread over several vertebral levels. Anteriorly, the epidural space is a potential space with the dura tightly adherent to the vertebral bodies and ligaments. Abscesses occur more frequently in the larger posterior epidural space. Most spinal epidural abscesses occur in the thoracic area, which is anatomically the longest of the spinal regions. Empiric antibiotic coverage should include antistaphylococcal antibiotics.

The clinical triad of fever, back pain, and neurologic deficit is not present in most patients. Frequently the patient gives a history of back strain or mild injury. An evident source of infection in skin or soft tissue may be found. IV drug users are a high-risk group. Occurrences have been cited even in patients with a remote history of IV drug abuse. Cases are frequently reported in patients with diabetes mellitus, which is a risk factor in 50% of reported patients; alcoholism; and conditions involving chronic immunosuppression.
Symptoms may include the following:
•Fever, present in only about one third of patients
•Localized back pain in most patients, often the first symptom
•Radiculopathy with radiating or lancinating pain, including chest or abdominal pain (At times this may simulate myocardial infarction or other causes of chest or abdominal pain.)
•Spinal cord syndromes, typically involving paraparesis with prospective progression to paraplegia (Epidural abscesses at the level of the cauda equina cause symptoms consistent with cauda equina syndrome rather than a spinal cord syndrome.) Physical findings vary with the degree of spinal cord compression or dysfunction. Central cord syndrome from epidural abscess has also been reported (from absent to hyperreflexia with clonus and extensor plantar (Babinski) responses. Areflexia may indicate spinal shock with transient inhibition of spinal reflexes).
•Sphincter dysfunction, including incontinence or increased residual urine volumes.
•Headache and neck pain may be present, especially with cervical epidural abscesses.

•Leukocytosis is present in about two thirds of patients. ESR may be highly elevated.
•Immediate imaging of the spine and spinal cord is imperative when the diagnosis is clinically suspected.If available, *spinal MRI is the procedure of choice*. Recall that symptoms are often defined by spinal cord level, while MRI is ordered by regional or vertebral levels. Because abscesses frequently extend for several levels, be certain to order the anatomically correct region. If MRI is unavailable, CT myelography or conventional myelography can reveal an intraspinal extramedullary mass—a "surgical" lesion.
•Lumbar puncture is relatively contraindicated if spinal epidural abscess is suspected. However, LP may be essential to exclude meningitis from the differential diagnosis. Lumbar puncture runs the risk of introducing purulent material into the subarachnoid space. Protein usually is elevated above 100 mg/dL, often a mixture of polymorphonuclear and mononuclear cells from 10-1000 leukocytes/µL.

http://emedicine.medscape.com/article/1165840-overview#a5

Emergent acute back pain. Epidural abscess or hematoma.

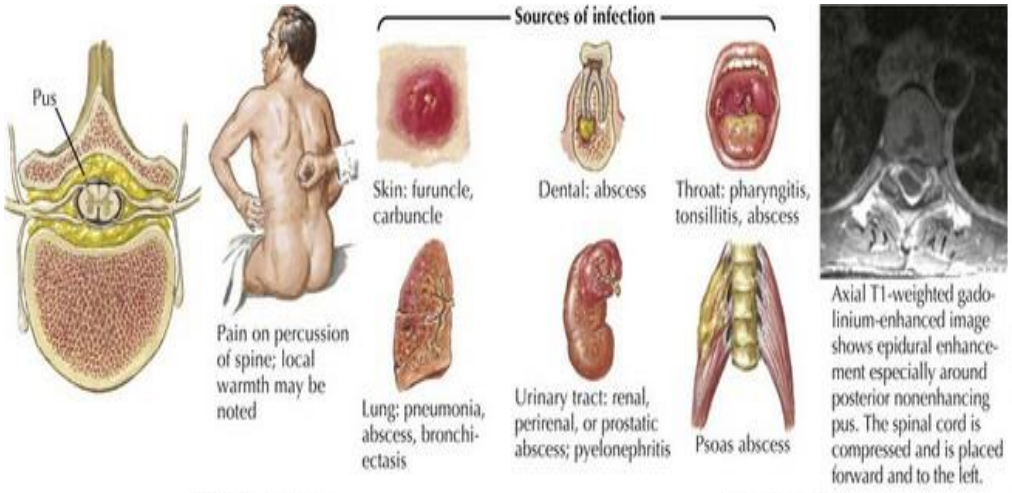

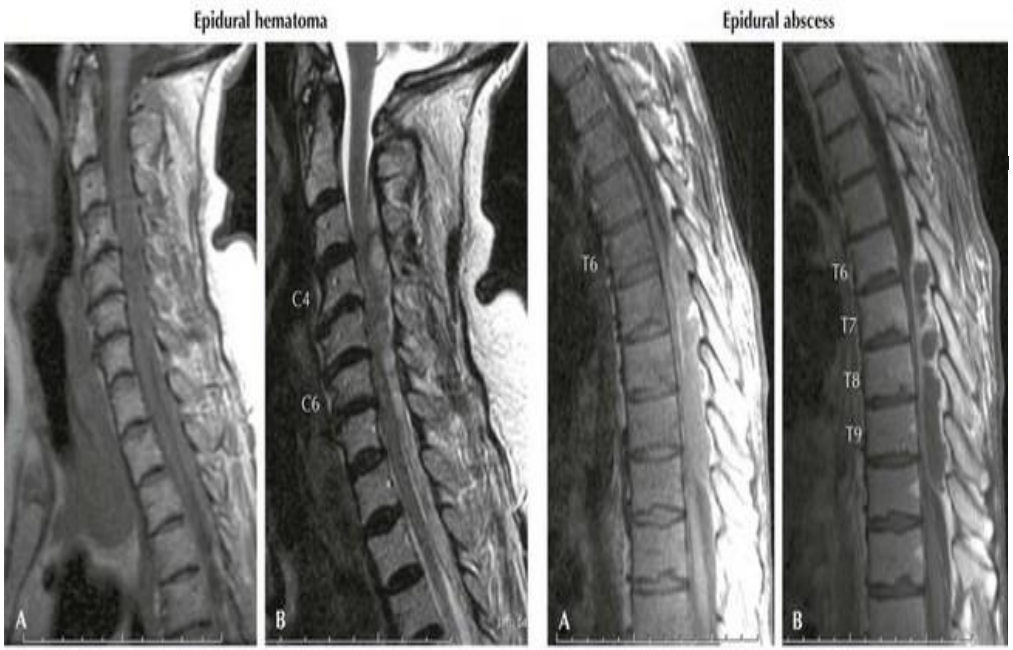

A. T1-weighted sagittal image shows a vague posterior epidural mass.

B. T2-weighted image shows heterogeneous collection posterior to spinal cord.

Sagittal T1-weighted images without (A) and with (B) gadolinium enhancement demonstrate an extensive posterior epidural process from T6 to T11. Enhancement of the granulation tissue allows appreciation of nonenhancing focal pus collections.

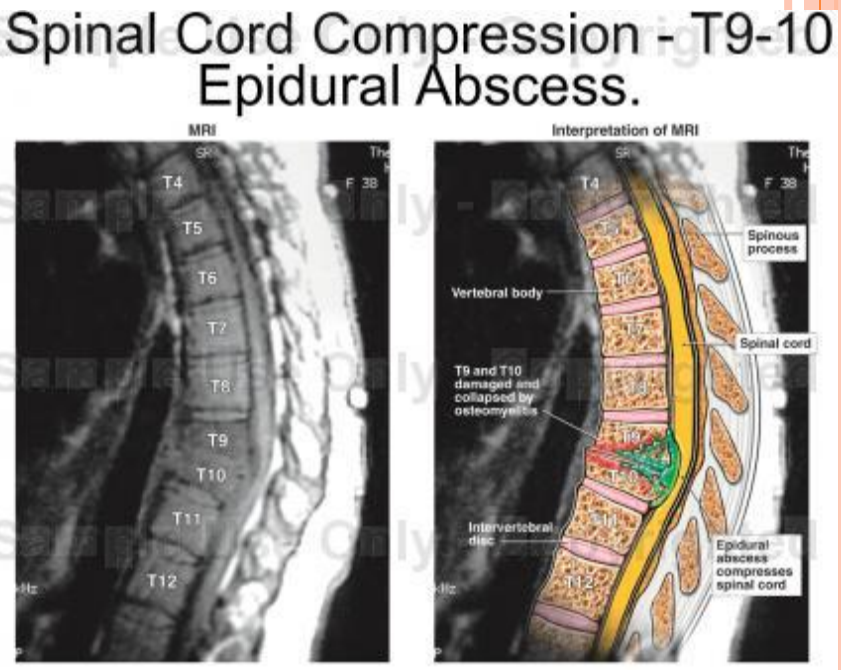

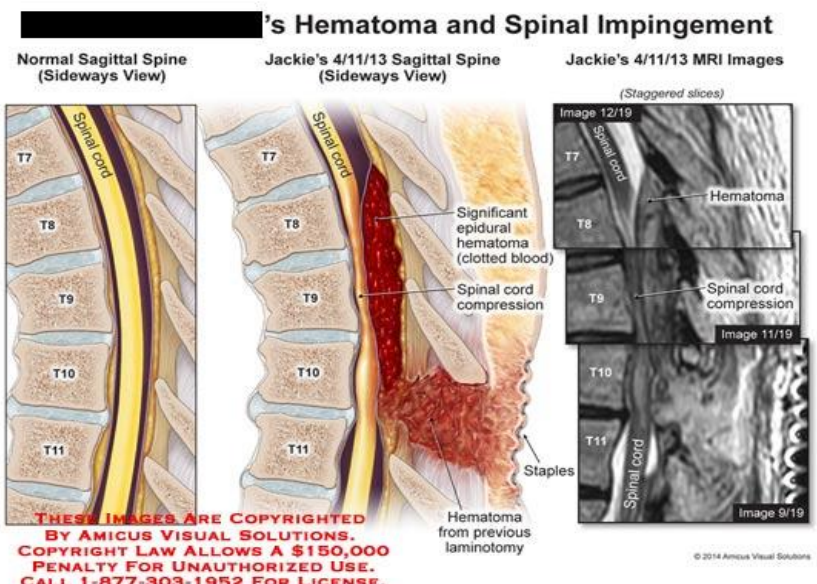

THESE IMAGES ARE COPYRIGHTED BY AMICUS VISUAL SOLUTIONS. COPYRIGHT LAW ALLOWS A $150,000 PENALTY FOR UNAUTHORIZED USE. CALL 1-877-303-1952 FOR LICENSE.

http://table-periodique.tk/lubox/spinal-hematoma-symptoms-2261.php

Emergent acute back pain. Meningitis.

Approximately 25% of patients have concomitant sinusitis or otitis that could predispose to *S pneumoniae* meningitis. In contrast, patients with subacute bacterial meningitis and most patients with viral meningitis present with neurologic symptoms developing over 1-7 days. Chronic symptoms lasting longer than 1 week suggest the presence of meningitis caused by certain viruses or by tuberculosis, syphilis, fungi (especially cryptococci), or carcinomatosis. As bacterial meningitis progresses, patients of any age may have seizures The classic triad of meningitis consists of fever, nuchal rigidity, and altered mental status, but not all patients have all 3, and almost all patients have headache. In patients who have previously been treated with oral antibiotics, seizures may be the sole presenting symptom. Nonblanching petechiae and cutaneous hemorrhages may be present in meningitis caused by *N meningitidis* (50%), *H influenzae, S pneumoniae*, or *S aureus*. Arthritis is seen with meningococcal infection and with *M pneumoniae* infection but is less common with other bacterial species. These symptoms can develop over several hours or over 1-2 days. Other symptoms can include the following:

- Nausea
- Vomiting
- Photalgia (photophobia)
- Sleepiness
- Confusion
- Irritability
- Delirium
- Coma

Systemic findings on physical examination may provide clues to the etiology of a patient's meningitis. Morbilliform rash with pharyngitis and adenopathy may suggest a viral etiology (eg, Epstein-Barr virus [EBV], cytomegalovirus [CMV], adenovirus, or HIV). Macules and petechiae that rapidly evolve into purpura suggest meningococcemia (with or without meningitis). Vesicular lesions in a dermatomal distribution suggest VZV. Genital vesicles suggest HSV-2 meningitis. Sinusitis or otitis suggests direct extension into the meninges, usually with *S pneumoniae* or, less often, *H influenzae.* Rhinorrhea or otorrhea suggests a cerebrospinal fluid (CSF) leak from a basilar skull fracture, with meningitis most commonly caused by *S pneumoniae.* Hepatosplenomegaly and lymphadenopathy suggest a systemic disease, including viral (eg, mononucleosislike syndrome in EBV, CMV, and HIV) and fungal (eg, disseminated histoplasmosis). The presence of a heart murmur suggests infective endocarditis with secondary bacterial seeding of the meninges.

Chronic meningitis

It is essential to perform careful general, systemic, and neurologic examinations, looking especially for the following:

- Lymphadenopathy
- Papilledema and tuberculomas during funduscopy
- Meningismus
- Cranial nerve palsies

The diagnostic challenges in patients with clinical findings of meningitis are as follows:

- Early identification and treatment of patients with acute bacterial meningitis
- Assessing whether a treatable central nervous system (CNS) infection is present in those with suspected subacute or chronic meningitis
- Identifying the causative organism
- Whenever the diagnosis of meningitis is strongly considered, a lumbar puncture should be promptly performed. Examination of the cerebrospinal fluid (CSF) is the cornerstone of the diagnosis. The diagnosis of bacterial meningitis is made by culture of the CSF sample. The opening pressure should be measured and the fluid sent for cell count (and differential count), chemistry (ie, CSF glucose and protein), and microbiology (ie, Gram stain and cultures).
- Elevated serum serum procalcitonin levels predict bacterial meningitis.

Emergent acute back pain. Spinal fractures.

Osteoporotic fractures (fragility fractures, low-trauma fractures) are those occurring from a fall from a standing height or less, without major trauma such as a motor vehicle accident. Vertebral compression fractures are the most common type of osteoporotic fracture. They often occur at the midthoracic (T7-T8) spine and the thoracolumbar junction (T12-L1). Fractures may result in significant back pain, limited physical functioning and activities of daily living, and can lead to loss of independence, depression, and chronic pain. Osteoporotic vertebral compression that occurs slowly over time is often asymptomatic. Old or healed fractures may be an incidental finding on radiographs of the chest or abdomen. In other patients, the presence of vertebral fractures may become apparent because of height loss or kyphosis. In contrast, acute episodes of significant vertebral body compression are associated with pain. The pain may be tolerable and resolve without medical intervention (but the patient can often recall the episode of pain when a fracture is incidentally found on other imaging) or the pain may be incapacitating, requiring hospital admission and parenteral opioids. The pain from a vertebral compression fracture is variable in quality and may be sharp or dull. Sitting, spine extension, Valsalva maneuver, and movement often aggravate the pain and may be accompanied by muscle spasms. Sleep may be disturbed by pain. On physical examination, the patient may experience pain upon palpation and percussion of the corresponding spinous process and paravertebral structures. Dual energy radiographic absorptiometry scanningis currently the most widely used method to measure bone mineral density.

http://www.uptodate.com/contents/osteoporotic-thoracolumbar-vertebral-compression-fractures-clinical-manifestations-and-treatment?source=see_link

Midline back pain is the hallmark symptom of lumbar compression fractures. The pain is axial, nonradiating, aching, or stabbing in quality and may be severe and disabling. The location of the pain corresponds to the fracture site, as seen on radiographs. In elderly patients with severe osteroporosis, however, there may be no pain at all as the fracture occurs spontaneously. Young adults may present with severe back pain following an accident, such as a fall or a motor vehicle accident. Lower extremity weakness or numbness are important symptoms of neurologic injury from the fracture. Alternatively, many compression fractures are painless. Osteoporotic compression fractures are often diagnosed when an elderly patient presents with symptoms such as progressive scoliosis or mechanical lower back pain and the physician obtains routine lumbar radiographs. Finally, patients may present with a known (or unknown) malignancy. Routine spinal screening via magnetic resonance imaging (MRI; if focal or referred pain occurs), or via bone scan (as a survey if pain has not occurred) reveals the pathologic fracture. The most common malignancies leading to spinal involvement in the form of fractures are metastasis and multiple myeloma. Upon inspection of the spine, the patient typically has a kyphotic posture that cannot be corrected. The kyphosis is caused by the wedge shape of the fractured vertebra; the fracture essentially turns the lateral conformation of the vertebra from a square to a triangle. Extreme pain elicited with superficial palpation is often observed in patients with spinal infections. Moderate pain is usually present at the level of the fracture. Radiography is the standard imaging study for spine fractures. Anteroposterior and lateral views of the lumbar and thoracic spines are usually the minimum studies needed. CT scanning evaluates the complexity of fractures seen on radiographs and to spot subtler fractures not readily seen on radiographs, accurately visualizes the amount of spinal canal compromise and middle canal involvement. All patients with wedge fractures with more than 50% loss of vertebral height should undergo CT scanning to rule out middle column and burst fractures. MRI is required when the patient describes lower extremity motor or sensory loss. Radicular pain is another indication for MRI.

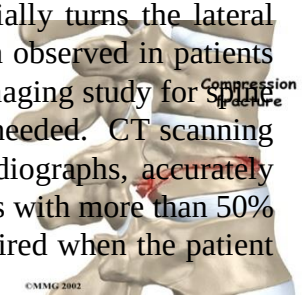

http://emedicine.medscape.com/article/309615-workup#c6

Urgent acute back pain

Disk herniation causing neurologic compromis	Malignancy	Transverse myelitis	Vertebral osteomyelitis	Spinal stenosis
Leg pain is greater than back pain and worsens when sitting; pain from L1-L3 nerve roots radiates to hip and/or anterior thigh, pain from L4-S1 nerve roots radiates to below the knee. Many patients with symptoms of acute lumbosacral radiculopathy improve gradually with supportive care	Pain worsens in prone position, spinous process tenderness, recent weight loss, fatigue. Pain is the most common symptom. In patients with a history of cancer, sudden, severe pain raises concern for pathologic fracture. Patients may also have neurologic symptoms from either spinal cord compression or spinal instability. A history of cancer (excluding nonmelanoma skin cancers) is the strongest risk factor for back pain from bone metastasis. Among solid cancers, metastatic disease from breast, prostate, lung, thyroid, and kidney cancers account for 80 percent of skeletal metastases. Approximately 60 percent of patients with multiple myeloma have skeletal lytic lesions present at diagnosis. Malignancy may manifest initially as a compression fracture. The most common malignancy in the spine is metastasis. Typical malignancies that metastasize to the spine are renal cell, prostate, breast, and lung, although other types can metastasize to the spine on rare occasions. The 2 most common primary spine malignancies are multiple myeloma and lymphoma. Nocturnal pain may be due to swelling of neoplastic tissues associated with inactivity in the supine position or to stretching of neural tissues over the neoplasticmass. Common primary sources of skeletal metastases include tumors of the breast, prostate, lung, kidney, thyroid, colon, uterine cervix, and bladder. Physical examination may demonstrate pain on palpation over the affected bone	Transverse myelitis is an inflammation of both sides of one section of the spinal cord. This neurological disorder often damages the insulating material covering nerve cell fibers (myelin). Transverse myelitis interrupts the messages that the spinal cord nerves send throughout the body. Transverse myelitis pain may begin suddenly in your lower back. Sharp pain may shoot down your legs or arms or around your chest or abdomen. Pain symptoms vary based on on the part of your spinal cord that's affected. Complains: stumbling or dragging one foot, or heaviness in the legs. Others may develop severe weakness or even total paralysis, needing to urinate more frequently, urinary incontinence, difficulty urinating and constipation, stiffness, tightness or painful spasms.	Constant pain, spinous process tenderness, often no fever, normal complete blood count, elevated erythrocyte sedimentation rate and/ or C-reactive protein level. Acute osteomyelitis typically presents with gradual onset of symptoms over several days. Most patients with vertebral osteomyelitis will present with back pain but may not have fevers or other systemic symptoms. Prompt antibiotic treatment improves outcomes.	Leg pain is greater than back pain; pain worsens with standing and walking, and improves with rest or when the spine is flexed; pain may be unilateral (foraminal stenosis) or bilateral (central or bilateral foraminal stenosis). Ambulation-induced pain localized to the calf and distal lower extremity resolving with sitting or leaning forward ("pseudoclaudication" or "neurogenic claudication") is a hallmark of lumbar spinal stenosis.
Radiculopathy refers to symptoms or impairments related to a spinal nerve root. Damage to a spinal nerve root may result from degenerative changes in the vertebrae, disc protrusion, and other causes. The clinical presentations of lumbosacral radiculopathy vary according the level of nerve root or roots involved. Over 90 percent are L5 and S1 radiculopathies. Patients present with pain, sensory loss,weakness, and/or reflex changes consistent with the nerve root involved 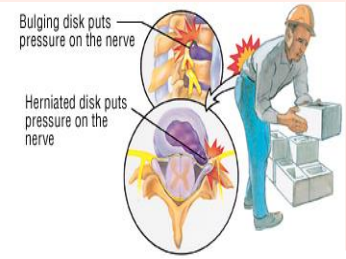 			Men are more commonly affected than women. Many cases are thought to be health care-related or postprocedural from hematogenous spread of bacteremia. Less specific risk factors include an immunocompromised state and injection drug use. 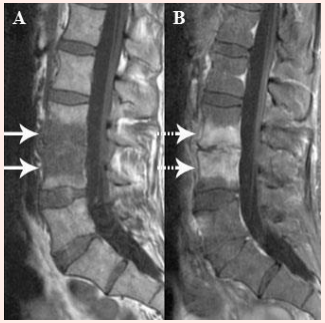 	Lumbar spinal stenosis (LSS) refers to an anatomic condition that includes narrowing of the intraspinal (central) canal, lateral recess, and/or neural foramena. Spondylosis, or degenerative arthritis affecting the spine, is the most common cause of LSS and typically affects individuals over the age of 60 years 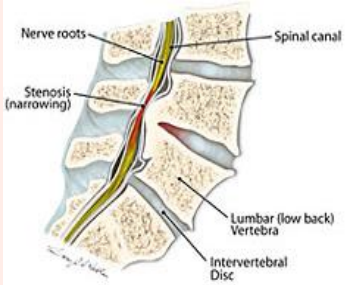

http://www.uptodate.com/contents/evaluation-of-low-back-pain-in-adults?source=see_link#H107855414

CHRONIC BACK PAIN

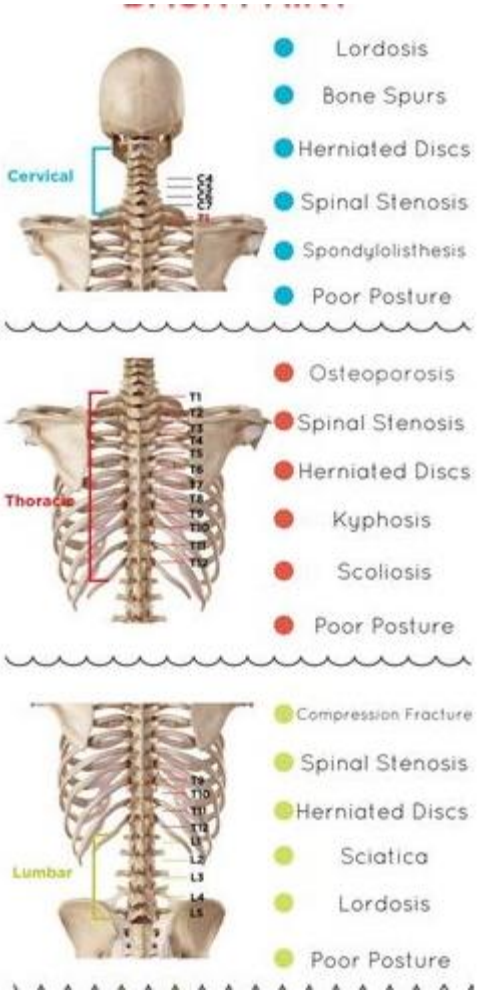

back pain is defined as chronic after 3 months because most normal connective tissues heal within 6-12 weeks, unless pathoanatomic instability persists.

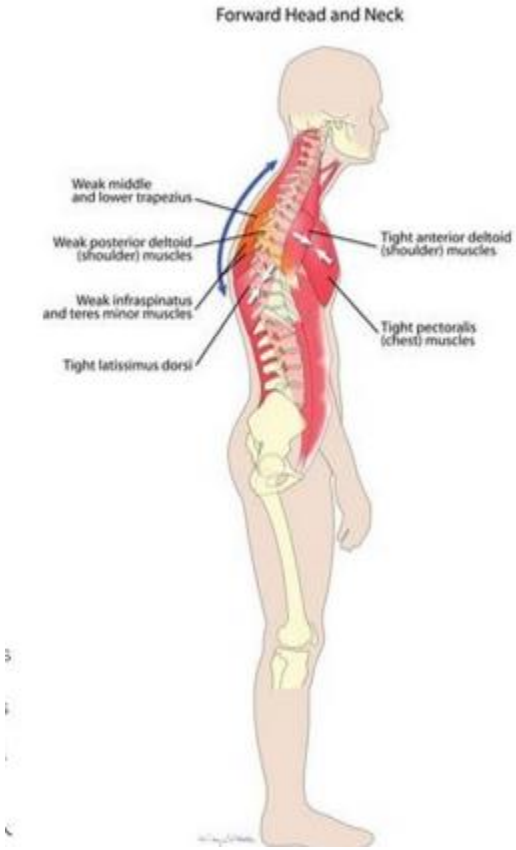

BACK PAIN, CHILDREN AND ADOLESCENTS

ICD-10CM # M54.5 Low Back Pain

M54.9 Dorsalgia

INFLAMMATORY OR INFECTIOUS

Diskitis.
Vertebral osteomyelitis (pyogenic, tuberculous).
Spinal epidural abscess.
Pyelonephritis.
Pancreatitis.

RHEUMATOLOGIC

Pauciarticular juvenile rheumatoid arthritis.
Reiter syndrome (reactive arthritis).
Ankylosing spondylitis.
Psoriatic arthritis.

DEVELOPMENTAL

Spondylolysis.
Spondylolisthesis.
Scheuermann disease.
Scoliosis.

Spinal Cord, Ganglia, and Nerve Roots

Intramedullary spinal cord tumor.
Sympathetic chain.
Ganglioneuroma.
Ganglioneuroblastoma.
Neuroblastoma.

TRAUMATICZ (ACUTE VERSUS REPETITIVE)

Hip-pelvis anomalies.
Herniated disk.
Overuse syndromes.
Vertebral stress fractures.
Upper cervical spine instability.

NEOPLASTIC

Vertebral Tumors

Benign

Eosinophilic granuloma.
Aneurysmal bone cyst.
Osteoid osteoma.
Osteoblastoma.

Malignant

Osteogenic sarcoma.
Leukemia.
Lymphoma.
Metastatic tumors.

OTHER

Intraabdominal or pelvic pathology.
Following lumbar puncture.
Conversion reaction.
Juvenile osteoporosis.

INFLAMMATORY OR INFECTIOUS BACK PAIN

Infections Patients with fever or weight loss (or both) may have an infection (or tumor) as a cause of their pain. The clinical findings in patients with a spinal infection depends on the infecting organism. Bacterial infections cause acute, toxic symptoms, whereas tuberculosis and fungal infections are indolent. The pain associated with bacterial infections is persistent, present at rest, and exacerbated by motion. Physical findings include decreased range of motion, muscle spasm, and tenderness on percussion over the involved bone. Technetium bone scintigraphy or MRI can be used to investigate for the presence of local infection. MRI also detects soft tissue extension of lesions beyond the bony confines of the vertebral column. CT should be performed after MRI evaluation to delineate the bony architecture of lesions not visualized adequately with MRI. Definitive diagnosis of infection is based on recovery and identification of the causative organism from blood cultures or from aspirated material or biopsy samples of the lesion. Antibiotic therapy is adequate to cure most spinal infections. Surgical intervention for drainage is necessary if neurologic dysfunction has occurred or appears imminent secondary to the infection.

INFECTIOUS DISORDERS AFFECTING THE LUMBOSACRAL SPINE*

- Vertebral osteomyelitis
  - Bacterial
  - Tuberculous
  - Fungal
  - Spirochetal
  - Parasitic
- Diskitis
- Pyogenic sacroiliitis

*All these disorders may cause localized low back pain.

Vertebral osteomyelitis

Vertebral osteomyelitis follows hematogenous spread from an extraosseous source. Organisms may enter bone from nutrient arteries or from the venous plexus of Batson, a valveless system of veins that supplies the spinal column. Organisms that cause osteomyelitis include bacteria, mycobacteria, fungi, spirochetes, and parasites. The primary sources for spinal infections include the genitourinary tract, respiratory tract, and skin. The most frequently encountered organism causing infection is *Staphylococcus aureus* (in 60% of cases). Gram-negative organisms may cause vertebral osteomyelitis in the elderly and in parenteral drug abusers (*Escherichia coli and Pseudomonas aeruginosa). In patients who have undergone* surgery or suffered trauma to the spine, generally nonpathogenic organisms (diphtheroids, *Staphylococcus epidermidis) may be associated with an indolent* infection of the vertebral column.65 Brucellosis may develop in workers in the meat-processing industry.66 Tuberculous and fungal infections of the vertebral column occur most often in the elderly and other immunocompromised individuals. The clinical findings in a patient with tuberculous spondylitis are an insidious onset (potentially over a period of months to years) of pain over the involved vertebrae, low-grade fever, and weight loss.

Pyogenic sacroiliitis

Pyogenic sacroiliitis is an unusual form of septic arthritis.70 The disease is associated with acute symptoms, severe sacroiliac joint pain, and fever. This entity can be seen in postpartum women and also in injection drug users. Diagnosis of the causative organism may be achieved by blood cultures, fluoroscopically directed fine-needle aspiration, or open biopsy. Antibiotic therapy for 6 weeks is usually adequate to eradicate the infection without the need for surgical drainage.

Rheumatology 6th Ed [2015]

INFLAMMATORY OR INFECTIOUS BACK PAIN

Disk infection

Spondylodiskitis occurs in the setting of concurrent extraspinal infection, and in adults it is also associated with lumbar disk surgery. The ESR is almost universally elevated in the case of established disk space infections and often exceeds 100 mm/hr along with the presence of leukocytosis. Plain radiographs may be normal at the onset of infection but will demonstrate increasing destruction with prolonged duration of infection. Radiographic evidence of established disk infection includes the following:

- Symmetric destruction of the adjacent endplate surfaces of two vertebrae
- Loss of disk height
- Reactive new bone formation
- Sclerosis of the bone endplates, with or without bone destruction or formation
- Soft tissue abscesses
- Kyphosis or subluxations after significant bone destruction has occurred

On CT, changes in the disk space and vertebral endplates can be seen, as can soft tissue abscesses. The diagnosis is confirmed by identifying the causative organism from blood cultures, aspirated disk material, or biopsy specimens of infected adjacent bone. Six weeks of parenteral antibiotics and possibly additional oral antibiotic therapy usually provide adequate treatment for patients with radiologic evidence of disk space infection and a positive culture. The ESR provides a method of assessing the efficacy of therapy in these patients. Surgical intervention, including drainage and debridement of spinal infections, is indicated in patients in whom paraparesis or paraplegia develops.

Common degenerative causes of low back pain

	Muscle strain	Spondylolisthesis	Herniated disk	Osteoarthritis	Spinal stenosis
Age (yr)	20-60	20-40	20-60	>40	>50
Pain pattern					
Initial location	Back	Back	Leg > back	Back > leg	Leg > back
Onset	Acute	Insidious	Acute	Insidious	Insidious
Standing	+	+	–	+	+
Sitting	–	–	+	–	–
Flexion	+	–	+	–	–
Extension	–	+	–	+	+
Straight leg raise	–	–	+	–	–
Plain radiograph	–	+	–	+	+

Rheumatology 6th Ed [2015]

RHEUMATOLOGIC BACK PAIN. Ankylosing spondylitis

Ankylosing spondylitis (Behterev disease), a spondyloarthropathy, is a chronic, multisystem inflammatory disorder involving primarily the sacroiliac joints and the axial skeleton.

Key components of the *patient history* that suggest ankylosing spondylitis include the following:
•Insidious onset of low back pain
•Onset of symptoms before age 40 years
•Presence of symptoms for more than 3 months
•Symptoms worse in the morning or with inactivity
•Improvement of symptoms with exercise

AS is classified as a spondyloarthropathy. Axial SpA is a disease which starts normally in the third decade of life, rarely (<5%) at an age older than 45 years, The spondyloarthropathies are linked by common genetics (the human leukocyte antigen [HLA] class-I gene *HLA-B27*) and a common pathology (enthesitis). HLA B27-positive patients have the first symptoms about 10 years earlier in comparison to HLA B27-negative patients.

Inflammatory back pain is the most common symptom and the first manifestation in approximately 75% of patients. The pain is typically dull and poorly localized to the gluteal and sacroiliac areas (SI). Symptoms associated with inflammatory back pain include insidious onset occurring over months or years, generally with at least 3 months of symptoms before presentation. Most patients have mild chronic disease or intermittent flares with periods of remission. The spinal disease is rarely persistently active.
The pain often begins unilaterally and intermittently, and generally begins in the lumbosacral region. However, as the disease progresses, it becomes more persistent and bilateral and progresses more proximally, with ossification of the annulus fibrosus that results in fusion of the spine (bamboo spine).
Patients commonly experience morning stiffness lasting at least 30 minutes, improvement of symptoms with moderate physical activity, and diffuse nonspecific radiation of pain into both buttocks. Patients often experience stiffness and pain that awakens them in the early morning, a distinctive symptom not generally found in patients with mechanical back pain.
New criteria to define inflammatory back pain have been proposed; when two of the four criteria are present, they yield a sensitivity of 70.3% and a specificity of 81.2%. *These criteria include the following:*
•Morning stiffness that lasts more than 30 minutes
•Improvement of back pain with exercise but not rest
•Nocturnal back pain during the second half of the night only
•Alternating buttock pain
•Acute onset of pain, exacerbation of symptoms with activity, and radicular radiation of pain suggest a mechanical or degenerative process such as disc disease.

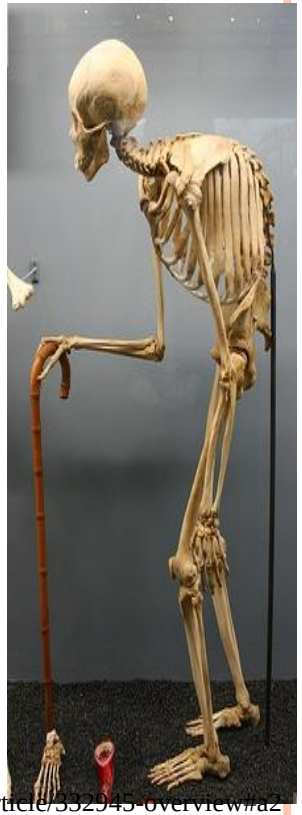

Patients with persistent back pain despite four to six weeks of conservative therapy who also have signs or symptoms concerning for ankylosing spondylitis should have a plain radiograph to evaluate the sacroiliac joints. These can often be well-evaluated on a lumbosacral plain radiograph.

http://emedicine.medscape.com/article/332945-overview#a2

RHEUMATOLOGIC BACK PAIN. Ankylosing spondylitis

Physical Examination

Chronic involvement of the spine eventually can lead to decreases in ROM and fusion of the vertebral bodies. Involvement of the cervical and upper thoracic spine can lead to fusion of the neck in a stooped forward-flexed position. This position can significantly limit the patient's ability to ambulate and look straight ahead. Stiffness of the spine and kyphosis resulting in a stooped posture are characteristic of advanced-stage AS. Earlier in the course of the disease, indirect evidence of sacroiliitis and spondylitis may be observed, including tenderness of the SI (elicited by either direct pressure or indirect compression) or a limited spinal ROM. Some patients may have a deformity of the spine, most commonly with a loss of lumbar lordosis and accentuated thoracic kyphosis.

Differentiation of inflammatory versus mechanical low back pain (LBP)

	Inflammatory LBP	Mechanical LBP
Age of onset	<40 yr	Any age (usually later)
Type of onset	Insidious	Acute
Symptom duration	>3 mo	<4 wk
Morning stiffness	≥30 min	<30 min
Nocturnal pain	Common	Absent
Effect of exercise	Improvement	Exacerbation
Sacroiliac joint tenderness	Frequent	Absent
Back mobility	Loss in all planes (late finding)	Abnormal flexion
Chest expansion	Often decreased	Normal
Neurologic deficits	Unusual	Possible

Schober test: 1) A mark is placed over the spinal column at a line that connects the posterior iliac spines; 2) Measure 10 cm caudally; 3) The patient bends forward as much as possible. With a normal examination, individuals will increase the distance between the two marks by at least 3–5 cm. The modified Schober test differs in that a second mark is made 5 cm below the first with the distance between the upper and lower marks measured. People with normal spinal mobility have an increase in the measured distance for the modified Schober test by at least 5 cm. (Courtesy of Dr GF Moore.)

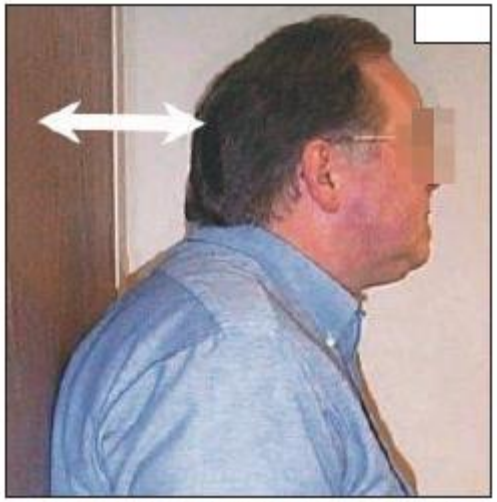

Occiput-to-wall distance is measured by asking the patient to stand with their feet against the wall; they are then asked to place their head as close to the wall as possible with the remaining distance between the occiput and wall measured. (Courtesy of Dr GF Moore.)

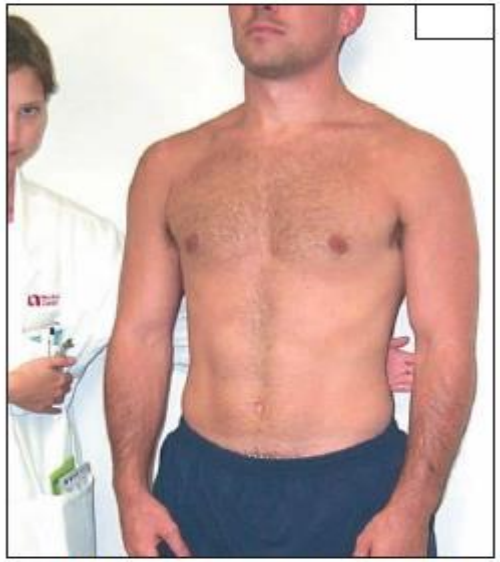

Four point examination: The patient is asked to stand facing away from a wall while touching their 1) occiput, 2) shoulder blades, 3) buttocks, and 4) heels against the wall. With normal lumbar lordosis, the examiner's hand should easily pass between the lumbar area and the wall. (Courtesy of Dr GF Moore.)

Rheumatology 6th Ed [2015]

RHEUMATOLOGIC BACK PAIN. Ankylosing spondylitis

1. Clinical criteria:

a. Low back pain and stiffness for more than 3 months which improves with exercise, but is not relieved by rest.

b. Limitation of motion of the lumbar spine in both the sagittal and frontal planes.

c. Limitation of chest expansion relative to normal values correlated for age and sex.

2. Radiological criterion:

Sacroiliitis grade ≥ 2 bilaterally or grade 3-4 unilaterally

Definite ankylosing spondylitis if the radiological criterion is associated with at least 1 clinical criterion.

Modified New York criteria for ankylosing spondylitis.

Reproduced with permission of John Wiley & Sons, Inc.

In patients with ≥ 3 months back pain and age at onset <45 years

Sacroiliitis on imaging* plus ≥ 1 SpA feature#	OR	HLA-B27 plus ≥ 2 other SpA features#

#SpA features

- inflammatory back pain
- arthritis
- enthesitis (heel)
- uveitis
- dactylitis
- psoriasis
- Crohn's/colitis
- good response to NSAIDs
- family history for SpA
- HLA-B27
- elevated CRP

*Sacroiliitis on imaging

- active (acute) inflammation on MRI highly suggestive of sacroiliitis associated with SpA
- definite radiographic sacroiliitis according to mod NY criteria

n=649 patients with back pain;
Sensitivity: 82.9%, Specificity: 84.4%
Imaging alone: Sensitivity: 66.2%, Specificity: 97.3%

ASAS classification criteria for axial spondyloarthritis.

Reproduced with permission from British Medical Journal and with permission from ASAS.

Rome Criteria

- Low back pain and stiffness for >3 months that is not relieved by rest
- Pain and stiffness in the thoracic region
- Limited motion in the lumbar spine
- Limited chest expansion
- History of uveitis

Diagnosis of ankylosing spondylitis when any clinical criteria present with bilateral sacroiliitis grade 2 or higher

Radiographic sacroiliac (SI) changes are graded as follows:

Grade 0 – Normal
Grade 1 – Suspicious
Grade 2 – Minimal sacroiliitis
Grade 3 – Moderate sacroiliitis
Grade 4 – Ankylosis

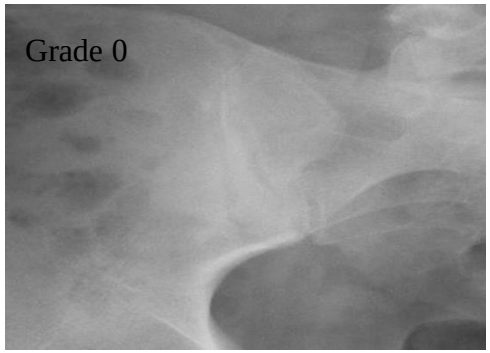

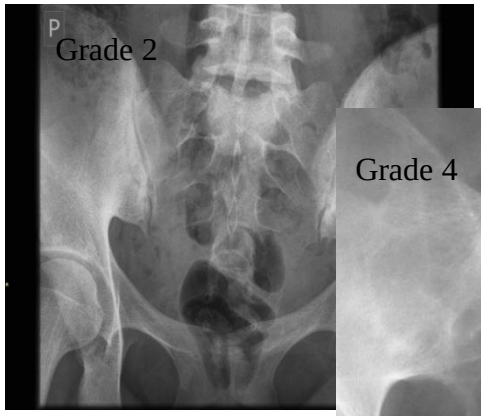

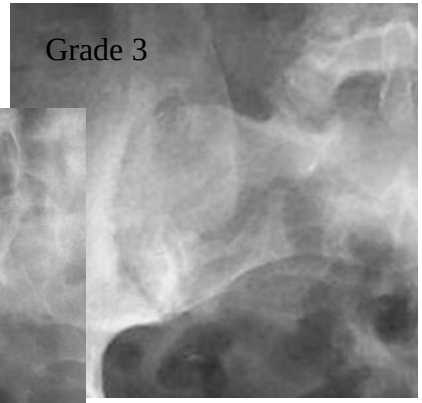

https://radiopaedia.org/articles/sacroiliitis-grading

RHEUMATOLOGIC BACK PAIN. Ankylosing spondylitis

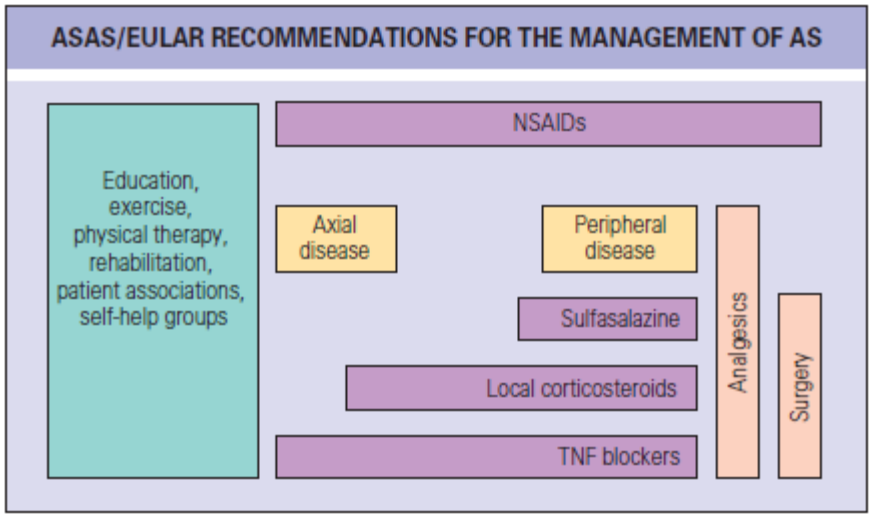

Management of AS should include an exercise program designed to maintain posture and range of motion. Nonsteroidal anti - inflammatory drugs (**NSAIDs**) are the first line of pharmacologic therapy for AS. These agents reduce pain and tenderness and increase mobility in many patients with AS. There is mounting evidence that continuous high-dose NSAI D slows radiographic progression, particularly in patients who are at higher risk for progression. However, many patients with AS have continued symptoms despite NSAID therapy and are likely to benefit from **anti-TNF-α therapy**. TNF is but one of many cytokines involved in the inflammatory cascade that may contribute to the symptoms of AS. Patients with AS treated with infliximab (chimeric human/mouse anti-TNF-α monoclonal antibody).

Sulfasalazine is useful in AS patients who do not respond to or who have contraindications to NSAIDs, as well as in those with coexisting IBD. In particular, it is often given to treat peripheral joint involvement, for which it has demonstrated efficacy. Sulfasalazine reduces spinal stiffness, peripheral arthritis, and the erythrocyte sedimentation rate (ESR), but there is no evidence that it improves spinal mobility, enthesitis, or physical function.

Secukinumab (Cosentyx) is a human IgG1 monoclonal antibody that selectively binds to and neutralizes the proinflammatory cytokine interleukin 17A (IL-17A). IL-17A is a naturally occurring cytokine that is involved in normal inflammatory and immune responses. Secukinumab was approved by the FDA for adults with active AS in January 2016.

Oral corticosteroids are occasionally helpful in controlling AS symptoms. However they should be used only for short-term management; long-term management carries a high risk of adverse effects. No evidence has shown that corticosteroids alter the outcome of the disease, and these agents are known to increase the tendency toward spinal osteoporosis.
Local corticosteroid injections are useful for symptomatic sacroiliitis, peripheral enthesitis, and arthritis, although the response is not typically as rapid as in patients with rheumatoid arthritis.

In adults with active AS:
•Strongly recommend treatment with nonsteroidal anti-inflammatory drugs (NSAIDs) over no treatment with NSAIDs
•Conditionally recommend continuous treatment with NSAIDs over on-demand treatment with NSAIDs
•No recommendation for any particular NSAID as the preferred choice
•Strongly recommend against treatment with systemic glucocorticoids

Rheumatology 6th Ed [2015]

RHEUMATOLOGIC BACK PAIN. Reiter syndrome (reactive arthritis).

Reactive arthritis (ReA), formerly termed Reiter syndrome, is an autoimmune condition that develops in response to an infection. It has been associated with gastrointestinal (GI) infections with *Shigella, Salmonella, Campylobacter,* and other organisms, as well as with genitourinary infections (especially with *Chlamydia trachomatis*). Reactive arthritis (ReA) usually develops 2-4 weeks after a genitourinary (GU) or gastrointestinal (GI) infection (or, possibly, a chlamydial respiratory infection. The onset of ReA is usually acute and characterized by malaise, fatigue, and fever. An asymmetrical, predominantly lower-extremity, oligoarthritis is the major presenting symptom. Myalgias may be noted early on. Asymmetric arthralgia and joint stiffness, primarily involving the knees, ankles, and feet (the wrists may be an early target), may be noted. Low-back pain occurs in 50% of patients. Both postvenereal and postenteric forms of ReA may manifest initially as nongonococcal urethritis, with frequency, dysuria, urgency, and urethral discharge; this urethritis may be mild or inapparent.

Sacroiliitis frequently occurs in adults who are positive for human leukocyte antigen (HLA)–B27 (though it is apparently less common in children). It is typically self-limiting. Whereas 50% of patients with ReA may develop low-back pain, most physical examination findings in patients with acute disease are minimal except for decreased lumbar flexion. Patients with more chronic and severe axial disease may develop physical findings similar to, or even indistinguishable from, those of ankylosing spondylitis.

Pharmacologic Therapy

NSAIDs (eg, indomethacin and naproxen) are the foundation of therapy for ReA.

Corticosteroids may be given either via intra-articular injection or as systemic therapy.

Empiric antibiotics may be considered after appropriate cultures have been taken.

Case reports have demonstrated the effectiveness of anti-TNF medications, such as etanercept and infliximab.

Tocilizumab, a humanized anti–IL-6 receptor antibody, may provide clinical benefit in patients who are refractory to conventional therapy or anti-TNF therapy.

A scoring system for diagnostic points in ReA-like spondyloarthropathies exists. In this system, the presence of 2 or more of the following points (1 of which must pertain to the musculoskeletal system) establishes the diagnosis:

- Asymmetric oligoarthritis, predominantly of the lower extremity
- Sausage-shaped finger (dactylitis), toe or heel pain
- Cervicitis or acute diarrhea within 1 month of the onset of arthritis
- Conjunctivitis or iritis
- Genital ulceration or urethritis

Spinal radiographic findings include sacroiliitis and syndesmophytes. Sacroiliitis (unilateral or bilateral) occurs in fewer than 10% of acute cases but develops in half of patients with chronic severe disease. Specifically ordering a radiograph of the sacroiliac joint is advisable. Syndesmophytes are asymmetric, paravertebral, bulky, discontinuous, comma-shaped ossifications that most commonly involve the lower thoracic and upper lumbar vertebrae

http://emedicine.medscape.com/article/331347-workup#c7

RHEUMATOLOGIC BACK PAIN. Psoriatic arthritis.

Psoriatic arthritis is a chronic inflammatory disease of both the skin and joints, as well as extraarticular features such as enthesitis and dactylitis, which is usually negative for rheumatoid factor.

Five different subtypes are generally recognized; however, some overlap may occur within individual patients:

– Distal interphalangeal joint–predominant arthritis
– Asymmetric oligoarticular arthritis
– Symmetric polyarticular arthritis

C-reactive protein is elevated in only about one-half of cases with PsA and the search for a reliable biomarker for outcome in PsA continues.

– *Axial disease predominant with spondylitis, sacroiliitis, and hip and shoulder involvement*
– Arthritis mutilans

Inflammation of the axial spine leading to pain and marked morning stiffness in addition to stiffness following periods of prolonged rest; this may be associated with sacroiliitis (more likely to be unilateral than in AS). In contrast to ankylosing spondylitis, this form of spinal disease carries a better prognosis, which may partly reflect the random nature of spinal involvement, as well as a lower frequency of zygapophyseal joint fusion than seen in psoriatic arthritis. Cervical spine involvement in psoriatic arthritis can occur as part of more widespread axial disease or as the sole site of axial involvement and becomes more frequent with time. Two main types of cervical spine changes are described: an ankylosing type, similar to that seen in ankylosing spondylitis, and an erosive or inflammatory type, which can result in atlantoaxial or subaxial instability. Because cervical spine involvement can be clinically silent, patients with psoriatic arthritis, particularly those with long-standing disease, should have cervical spine radiographs taken and evaluated before receiving general anesthesia.

Key radiographic features of PsA have been defined as joint erosions, joint space narrowing, bony proliferation, osteolysis (including pencil-in-cup deformity), ankylosis, and new bone formation at entheses, both central and peripheral, extensive extracapsular infl ammation seen in PsA on mRI.

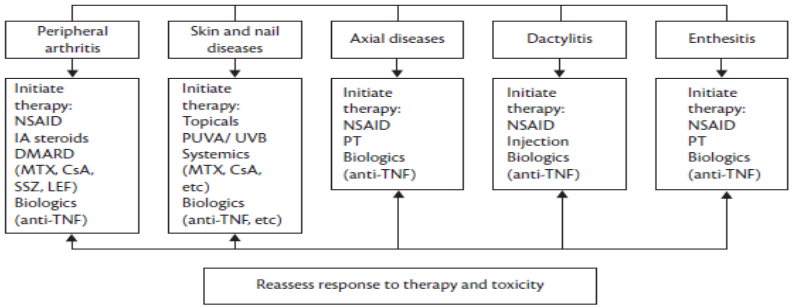

NSAIDs are useful in the treatment of PsA and provide relief of symptoms such as pain and stiffness, although published evidence of their effect on PsA is limited. However, NSAIDs do not prevent disease progression and may worsen skin lesions. Glucocorticoid therapy in the form of intraarticular injections of corticosteroids (triamcinolone, methylprednisolone) is often used when only one or a few joints are affected. Methotrexate (MTX) is one of the most commonly used systemic medications for PsA despite limited evidence of efficacy. Patients being treated long-term with MTX must undergo regular blood monitoring (blood cell counts, liver function tests, and serum creatinine) at least every 3 months.

Rheumatology 6th Ed [2015]

DEVELOPMENTAL BACK PAIN

Spondylolysis

Spondylolysis is a unilateral or bilateral defect (fracture or separation) in the vertebral pars interarticularis, usually in the lower lumbar vertebrae. Leg pain is greater than back pain; pain worsens with standing and walking, and improves with rest or when the spine is flexed; pain may be unilateral or bilateral. In young athletes, spondylolysis usually represents a fatigue fracture in the posterior arch of the spine, specifically the bony area of the pars interarticularis (pars) between the zygapophyseal (facet) joints. Although usually an overuse injury, spondylolysis may present following an acute overload. Several observations suggest spondylolysis is primarily a fatigue fracture. Spondylolysis occurs at the fifth lumbar vertebra (L5) approximately 85 to 95 percent of the time.

The physical examination of patient with lumbosacral spondylolysis (lumbar spondylolysis) frequently yields minimal findings.No tenderness to palpation is noted. Sciatica can occur but is rare. Hyperextension mimicking the sporting movement generally elicits pain. Routine thoracolumbar radiography found the pars defect is represented by the collar on the Scotty dog.

Spondylolisthesis

Spondylolisthesis can be described according to its degree of severity. The spondylolisthesis is graded by measuring how much of a vertebral body has slipped forward over the body beneath it. It becomes apparent more often in people who are involved with very physical activities such as weightlifting, gymnastics, or football. Can cause back pain in adolescents, although it is unclear whether it causes back pain in adults; pain worsens with spine extension and activity. to lumbar strain; disk pain often worsens with flexion activity or sitting, facet pain often worsens with extension activity, standing, or walking.

•Pain in the low back, especially after exercise

•Increased lordosis (ie, swayback).

•Pain and/or weakness in one or both thighs or legs

•Reduced ability to control bowel and bladder functions

•Tight hamstring musculature

•Changes may occur in the way people stand and walk

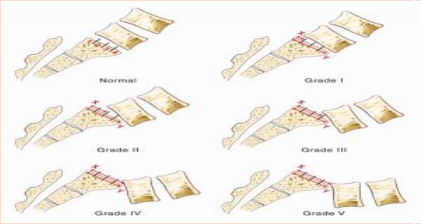

Scheuermann disease

Scheuermann, or Scheuermann's, disease (juvenile kyphosis) is a deformity in the thoracic or thoracolumbar spine in which pediatric patients have an increased kyphosis along with backache and localized changes in the vertebral bodies. (osteochondrosis of the secondary ossification centers of the vertebral bodies). *Radiologic criteria for the diagnosis of the condition:*

•Hyperkyphosis greater than 40°

•Irregular upper and lower vertebral endplates with loss of disk space height

•Wedging of 5° or more in three consecutive vertebrae

•A history of deformity with complain of discomfort in the region of the kyphosis best demonstrated in the forward flexed position, usually intermittent and is characterized as dull and aching; it is related generally to activity and is relieved by rest.

•A high association exists between scoliosis and Scheuermann's disease. Patients also may have a hyperlordosis in the lumbar spine.

•Hamstring tightness may be present, neurologic deficits are extremely rare.

•In patients with curves greater than 75° and with pain that is unresponsive to nonoperative measures, consider spinal fusion.

Bertolotti's syndrome

Back pain in the setting of a transitional vertebra is known as "Bertolotti's syndrome." A transitional vertebra is a common finding on radiologic studies. It is a congenital anomaly with a naturally occurring articulation or bony fusion between the transverse processes of L5 and the sacrum. Estimates of prevalence of transitional vertebra range from 4 to 36 percent. It remains unclear whether these individuals have a higher risk of back pain than those without such an anomaly. Generally, patients with Bertolotti's syndrome should initially be treated similarly as patients with nonspecific back pain. Whether and when surgical intervention is appropriate remains unclear.

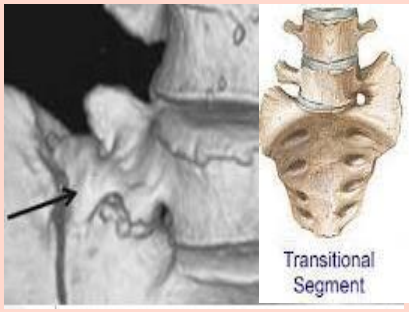

http://www.uptodate.com/contents/evaluation-of-low-back-pain-in-adults?source=see_link#H107855414

MALIGNANT (neoplastic) BACK PAIN

Osteoid osteoma

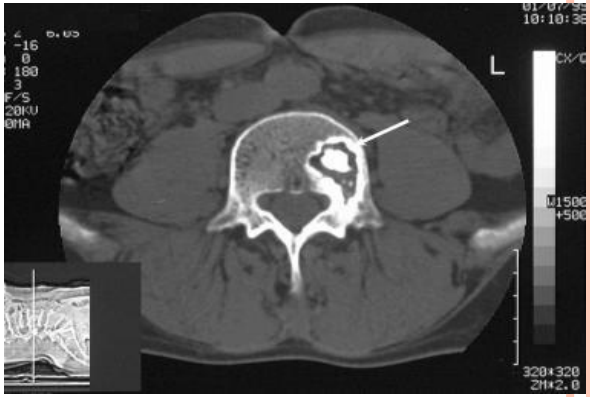

Osteoid osteoma is a benign tumor of bone. Approximately 7% of osteoid osteomas occur in the spine, most frequently in the lumbar area. The pain is aching and boring and frequently worse at night. The appearance of marked paravertebral muscle spasm and sudden onset of nonstructural scoliosis in a young adult requires an evaluation for this lesion, which typically occurs on the concave side of the scoliosis. The pain is often relieved by low-dose NSAID therapy. Hyperemia of the tumor may cause swelling and erythema of the skin if the lesion is superficial. The radiographic finding of a lucent nidus with a diameter of 1.5 cm and a surrounding well-defined area of dense sclerotic bone is virtually pathognomonic of osteoid osteoma. Bone scan or CT should be performed if an osteoma is suspected and not found on plain radiographs. Treatment of an osteoid osteoma is simple excision of the nidus and surrounding sclerotic bone.

Multiple myeloma

Multiple myeloma is the most common primary malignancy of bone in adults Patients typically range in age from 50 to 70 years. Low back pain is the initial complaint in 35% of patients. The pain is aching and intermittent at onset, aggravated by weight bearing, and improved with bed rest. Some patients may have radicular symptoms. Significant neurologic dysfunction, including paraplegia, occurs more commonly with solitary plasmacytoma than with multiple myeloma. Physical examination may demonstrate diffuse bone tenderness, fever, pallor, and purpura in the later stages of the illness. Spinal cord compression may occur with vertebral body collapse.

Abnormal laboratory results may include anemia, leukocytosis, thrombocytopenia, elevated ESR, hypercalcemia, hyperuricemia, elevated creatinine, and a positive Coombs test. An increase in serum proteins is secondary to the presence of abnormal immunoglobulins in any of the five classes. Urinalysis may detect Bence Jones protein formed by the production of excess immunoglobulin light chains. Bone marrow aspiration or biopsy reveals an excess number of plasma cells of varied histologic grades.

Plain radiographs demonstrate osteolysis without reactive sclerosis and sparing of the posterior elements of the spine. Bone scintigraphy does not detect myeloma because of the absence of a reactive Component of osteoblasts to the myeloma cells. MRI and CT are better Techniques for identifying the presence and extent of myeloma lesions in bone and soft tissues. MRI is able to detect spinal bone marrow involvement in Patients with asymptomatic myeloma. Myeloma is treated with chemotherapeutic agents to control growth of the malignant plasma cells. In patients with cord compression, decompression laminectomy is indicated, with or without local radiotherapy.

Rheumatology 6th Ed [2015]

BACK PAIN
VISCEROGENIC ORIGIN

BACK PAIN, VISCEROGENIC ORIGIN

ICD-10CM # F45.41 Pain Disorder Exclusively

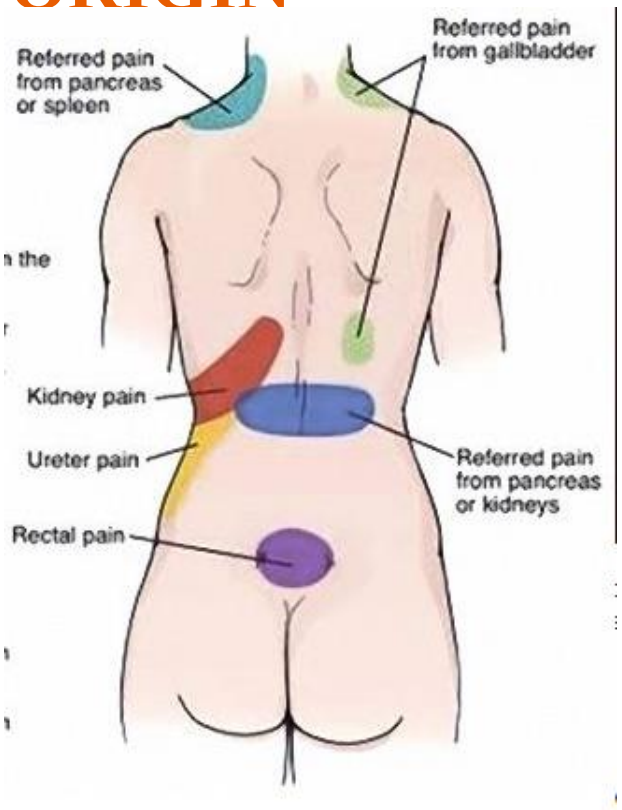

Related to Psychological Factors
M54 Dorsalgia
M54.5 Low back pain
Urolithiasis.
Aortic aneurysm. Aortic dissection.
Colorectal carcinoma.
Endometriosis.
Tubal pregnancy.
Prostatitis.
Peptic ulcer.
Pancreatitis.
Diverticular spasm.
Metastatic neoplasm (e.g., bladder, uterus, ovary, kidney).

The pain is typically characterized as acute if it lasts for under 4 weeks, subacute if it lasts between 4 and 12 weeks, and chronic if it lasts for more than 12 weeks.

FERRI'S CLINICAL ADVISOR 2017: 5 BOOKS IN 1

Urolithiasis Back Pain

Acute onset of severe flank pain radiating to the groin, gross or microscopic hematuria, nausea, and vomiting not associated with an acute abdomen are symptoms that most likely indicate renal colic caused by an acute ureteral or renal pelvic obstruction from a calculus. Location and quality of pain are related to position of the stone within the urinary tract. Severity of pain is related to the degree of obstruction, presence of ureteral spasm, and presence of any associated infection. Stones obstructing the ureteropelvic junction may present with mild-to-severe deep flank pain without radiation to the groin, due to distention of the renal capsule. Stones impacted within the ureter cause abrupt, severe, colicky pain in the flank and ipsilateral lower abdomen with radiation to the testicles or the vulvar area. Intense nausea, with or without vomiting, usually is present. Pain from upper ureteral stones tends to radiate to the flank and lumbar areas. Midureteral calculi cause pain that radiates anteriorly and caudally. This midureteral pain in particular can easily mimic appendicitis on the right or acute diverticulitis on the left. Distal ureteral stones cause pain that tends to radiate into the groin or testicle in the male or labia majora in the female because the pain is referred from the ilioinguinal or genitofemoral nerves. Stones lodged at the ureterovesical junction also may cause irritative voiding symptoms, such as urinary frequency and dysuria. If a stone is lodged in the intramural ureter, symptoms may appear similar to cystitis or urethritis.

The **acute renal colic attack** tends to occur early in the morning or at night, waking the patient from sleep, with the pain reaching its peak in most patients within 2 hours of onset. The pain roughly follows the dermatomes of T-10 to S-4. The classic patient with renal colic is writhing in pain, pacing about, and unable to lie still, in contrast to a patient with peritoneal irritation, who remains motionless to minimize discomfort.

The diagnosis of stone is often made on the basis of clinical symptoms alone, although confirmatory tests are usually performed. Approximately 85% of all patients with renal colic demonstrate at least microscopic hematuria, Urinary crystals of calcium oxalate, uric acid, or cystine may occasionally be found. A urine pH greater than 7 suggests presence of urea-splitting organisms, such as *Proteus, Pseudomonas,* or *Klebsiella* species, and struvite stones. A urine pH less than 5 suggests uric acid stones.
A high serum uric acid level may indicate gouty diathesis or hyperuricosuria, while hypercalcemia suggests either renal-leak hypercalciuria (with secondary hyperparathyroidism) or primary hyperparathyroidism. If the serum calcium level is elevated, serum PTH levels should be obtaine. 24-hour urine chemistry findings may be within the reference range in patients who actively form stones and who are at high risk for stones.
Use bedside ultrasonography if the patient's condition is potentially unstable. CT scan is a reasonable alternative in the stable patient. Plain abdominal radiography (also referred to as flat plate or KUB radiography) is useful for assessing total stone burden, as well as the size, shape, composition, and location of urinary calculi in some patients. Calcium-containing stones (approximately 85% of all upper urinary tract calculi) are radiopaque, but pure uric acid, indinavir-induced, and cystine calculi are relatively radiolucent on plain radiography. A nuclear renal scan can be used to objectively measure differential renal function, especially in a dilated system for which the degree of obstruction is in question. This is also a reasonable study in pregnant patients, in whom radiation exposure must be limited.

http://emedicine.medscape.com/article/437096-workup#c14

Urolithiasis Imagine

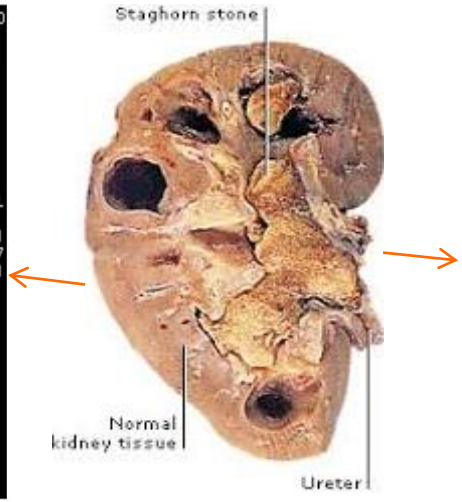

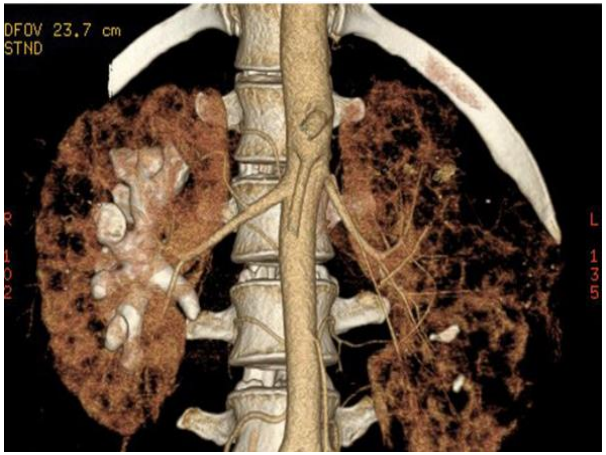

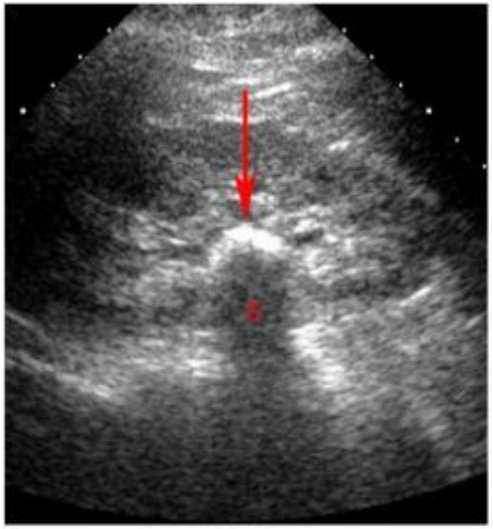

Ultrasound with kidney stone

KUB X-ray with ureteric stone

IVU – the contrast outlines drainage of kidneys

Non-contrast CT scan – offers the best resolution for detection.

http://www.spinabifida.net/spina-bifida-urolithiasis-kidney-stones-urinary-tract-stones-etc.html

Abdominal Aortic Aneurysm (AAA) Back Pain

The classic presentation of pain associated with hypotension, tachycardia, but back pain can be caused by erosion of the AAA into adjacent vertebrae. Also may cause symptoms from local compression, including early satiety, nausea, vomiting, urinary symptoms, or venous thrombosis from venous compression. AAAs are palpated in the upper abdomen; the aorta bifurcates into the iliac arteries just above the umbilicus. An abdominal bruit is nonspecific for an unruptured aneurysm, but the presence of an abdominal bruit or the lateral propagation of the aortic pulse wave can offer subtle clues and may be more frequently found than a pulsatile mass. Bruits may also indicate the presence of renal or visceral artery stenosis; a thrill is possible with aortocaval fistulae. The diagnosis should be entertained whenever a patient older than 50 years presents with abdominal pain, particularly when pain is associated with syncope or signs of hemorrhagic shock.

No specific laboratory studies exist that can be used to make the diagnosis of AAA. Ultrasonography is the standard imaging tool for AAA. Bedside emergency ultrasonography should be performed immediately if AAA is suspected.

Plain radiography is often performed on patients with abdominal complaints before the diagnosis of AAA has been entertained. Using this method to evaluate patients with AAA is difficult because the only marginally specific finding, aortic wall calcification, is seen less than half of the time.

CT has a sensitivity of nearly 100% for detecting AAA, and it has certain advantages over ultrasonography for defining aortic size, rostral-caudal extent, involvement of visceral arteries, and extension into the suprarenal aorta (see the image below). Spiral (helical) CT allows three-dimensional (3D) imaging of abdominal contents, facilitating detection of branch vessel and adjacent organ involvement. Arteriography may miss an AAA if there is a lack of calcification because of the laminated thrombus within the AAA making a more normal-appearing aortic lumen.

Thoracic aortic aneurysms occur most often in people age 65 and older. Symptoms often begin suddenly when: aneurysm grows quickly, rupture, aortic dissection. Symptoms and findings are similar to AAA.

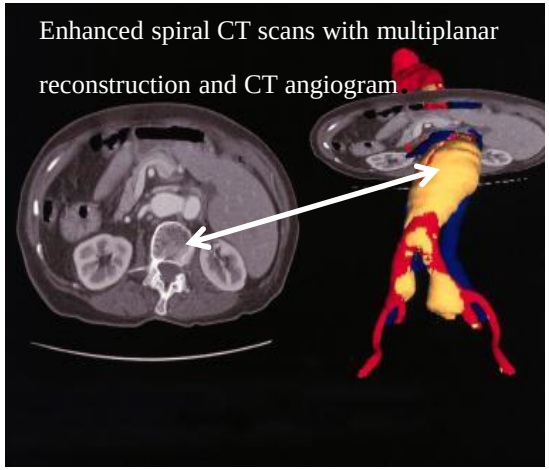

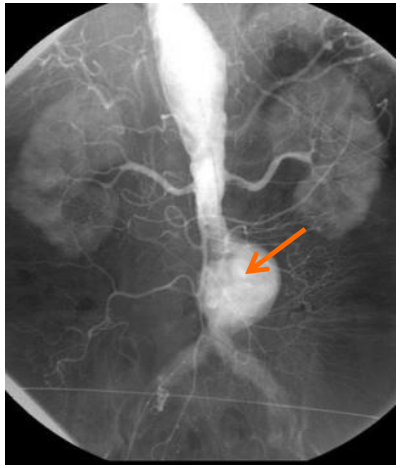

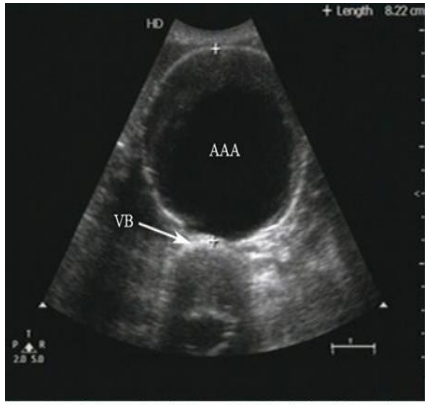

Source: Carmody KA, Moore CL, Feller-Kopman D: *Handbook of Critical Care and Emergency Ultrasound*: www.accessanesthesiology.com

Copyright © The McGraw-Hill Companies, Inc. All rights reserved.

http://emedicine.medscape.com/article/1979501-workup#c9

Colorectal carcinoma Back Pain

- Unexplained, persistent nausea or vomiting
- Unexplained weight loss
- Change in frequency or character of stool (bowel movements)
- Small-caliber (narrow) or ribbon-like stools
- Sensation of incomplete evacuation after a bowel movement
- Back pain (metastasis of the main tumor)

If there is a cancerous growth in the spinal column, back pain can be one of the main symptoms. The expansion of the cancer in the bone may weaken the bone. As a result, there is greater chance for spinal fractures to occur. Moreover, this may also cause spinal instability and compression of the nerves.

Routine laboratory studies should include a complete blood count (CBC); serum chemistries, including liver and renal function tests; and a carcinoembryonic antigen (CEA) test. A cancer antigen (CA) 19-9 assay, if available, may also be useful to monitor the disease.

Screening CBC may demonstrate a hypochromic, microcytic anemia, suggesting iron deficiency. The combined presence of vitamin B-12 or folate deficiency may result in a normocytic or macrocytic anemia. All men and postmenopausal women with iron deficiency anemia require a GI evaluation.

A suspicion of colorectal cancer diagnosis warrants rectal examination and colonoscopy with a biopsy of any suspicious lesions. The National Comprehensive Cancer Network recommends that all patients younger than 70 years of age who are diagnosed with colorectal cancer be tested for hereditary nonpolyposis colon cancer syndrome

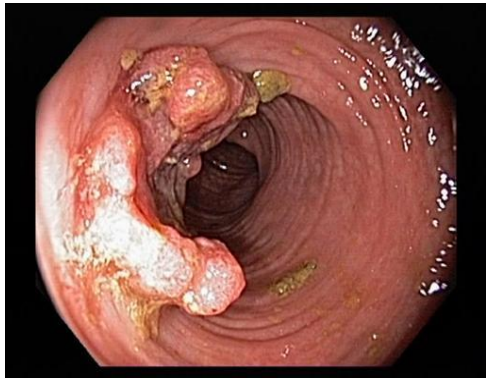

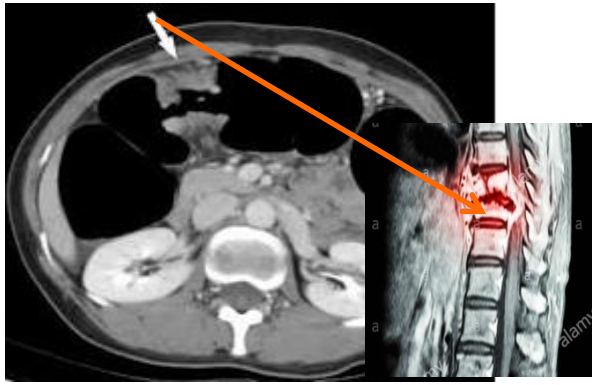

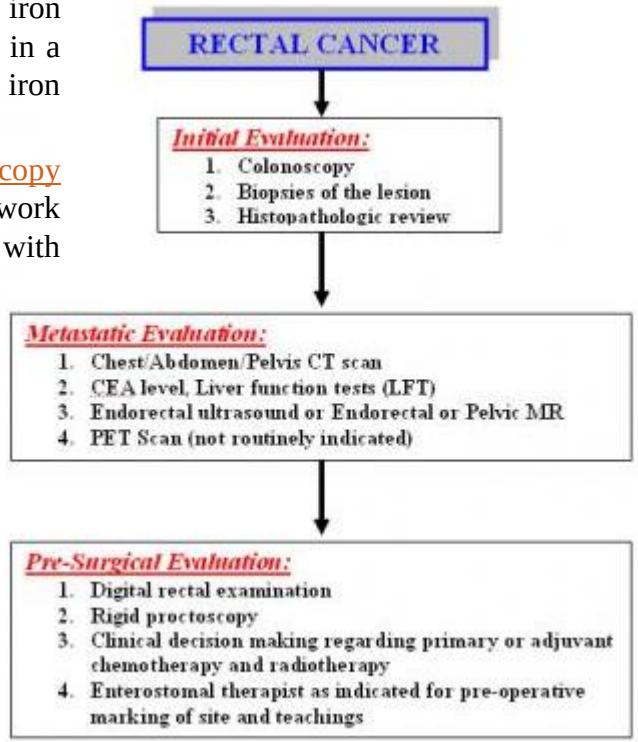

http://emedicine.medscape.com/article/281237-workup

Endometriosis Back Pain

Endometriosis is a common cause of pelvic pain in women. It is characterized by the overgrowth of uterine tissues; cells from this tissue implant in other structures in the pelvis – fallopian tubes, ovaries, bowel, bladder and rectum – and create abnormal growths. While certainly not a typical cause of **lower back pain** in women, medical professionals should be aware of the potential for uterine cells to impact the spine. When imaging tests show lesions or growths on the spine, endometriosis should be considered as a potential cause. Because most endometriotic implants are found on the uterus, ovaries, and posterior peritoneum, the patient usually presents with a history of progressively increasing pelvic pain and/or secondary dysmenorrhea. Discomfort in lower abdomen, pelvis, or hip

Common signs and symptoms of endometriosis may include:
Dysmenorrhea
Heavy or irregular bleeding
Pelvic pain
Lower abdominal or back pain [2]
Dyspareunia
Dyschezia (pain on defecation) - Often with cycles of diarrhea and constipation
Bloating, nausea, and vomiting
Inguinal pain
Pain on micturition and/or urinary frequency
Pain during exercise

Endometriosis. Red lesions on the sigmoid colon and cul-de-sac.

Patients with endometriosis do not frequently have any physical findings beyond tenderness related to the site of involvement. Laparoscopy is considered the primary diagnostic modality for endometriosis. Histologic demonstration of a combination of endometrial glands and stroma in biopsy specimens obtained from outside the uterine cavity is required to make the diagnosis of endometriosis.

Ultrasonography:Endometriosis can be assessed by either transvaginal ultrasonography or endorectal ultrasonography. Transvaginal ultrasonography is a useful method of identifying the classic chocolate cyst of the ovary. The typical appearance is that of a cyst containing low-level homogenous internal echoes consistent with old blood.

MRI is helpful in detecting rectal involvement and has been shown to accurately detect rectovaginal endometriosis and cul-de-sac obliteration in more than 90% of cases when ultrasonographic gel was inserted in the vagina and rectum.

Laparoscopy: the classic lesions are blue-black or have a powder-burned appearance. However, the lesions can be red, white, or nonpigmented. Peritoneal defects and adhesions are also indicative.

http://emedicine.medscape.com/article/271899-workup#c10

Ectopic pregnancy back pain

The classic clinical triad of ectopic pregnancy is as follows:
Abdominal pain
Amenorrhea
Vaginal bleeding

The following symptoms have also been reported:
Painful fetal movements (in the case of advanced abdominal pregnancy)
Dizziness or weakness
Fever
Flulike symptoms
Vomiting
Syncope
Cardiac arrest
The presence of the following signs suggests a surgical emergency:
Abdominal rigidity
Involuntary guarding
Severe tenderness
Evidence of hypovolemic shock (eg, orthostatic blood pressure changes, tachycardia)
Findings on pelvic examination may include the following:
The uterus may be slightly enlarged and soft
Uterine or cervical motion tenderness may suggest peritoneal inflammation
An adnexal mass may be palpated but is usually difficult to differentiate from the ipsilateral ovary
Uterine contents may be present in the vagina, due to shedding of endometrial lining stimulated by an ectopic pregnancy

Laparoscopic picture of an unruptured right ampullary tubal pregnancy; bleeding out of the fimbriated end has resulted in hemoperitoneum.

Diagnosis:

1. Serum and urine assays for the beta subunit of human chorionic gonadotropin (β-HCG) have been developed to detect a pregnancy before the first missed period.
2. serum estradiol, inhibin, pregnancy-associated plasma protein A, pregnanediol glucuronide, placental proteins, creatinine kinase, and a quadruple screen of serum progesterone, beta–human chorionic gonadotropin (β-HCG), estriol, and alfa-fetoprotein (AFP).
3. Ultrasonography is probably the most important tool for diagnosing an extrauterine pregnancy: absence of intrauterine sac, with or without fetal cardiac activity
4. Culdocentesis is another rapid and inexpensive method of evaluation for ruptured ectopic pregnancy. It is performed by inserting a needle through the posterior fornix of the vagina into the cul-de-sac and attempting to aspirate blood. When nonclotting blood is found in conjunction with a suspected ectopic pregnancy, operative intervention is indicated.
5. Patients in pain and/or those who are hemodynamically unstable should proceed to laparoscopy. Laparoscopy allows assessment of the pelvic structures, the size and exact location of the ectopic pregnancy, the presence of hemoperitoneum etc.

http://emedicine.medscape.com/article/2041923-workup#c14

Peptic ulcer back pain

Pain radiating to the back may suggest that an ulcer has penetrated posteriorly, or the pain may be pancreatic in origin.

Other possible manifestations include the following:
Dyspepsia, including belching, bloating, distention, and fatty food intolerance
Heartburn
Chest discomfort
Hematemesis or melena resulting from gastrointestinal bleeding. Melena may be intermittent over several days or multiple episodes in a single day.
Rarely, a briskly bleeding ulcer can present as hematochezia.
Symptoms consistent with anemia (eg, fatigue, dyspnea) may be present
Sudden onset of symptoms may indicate perforation.
NSAID-induced gastritis or ulcers may be silent, especially in elderly patients.
Only 20-25% of patients with symptoms suggestive of peptic ulceration are found on investigation to have a peptic ulcer.

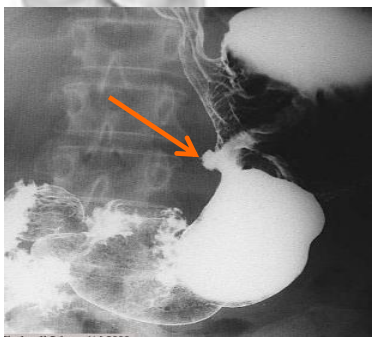

Diagnosis:
1.H pylori testing
2. Upper gastrointestinal (GI) endoscopy is the preferred diagnostic test in the evaluation of patients with suspected peptic ulcer disease. At endoscopy, gastric ulcers appear as discrete mucosal lesions with a punched-out smooth ulcer base, which often is filled with whitish fibrinoid exudate. Benign ulcers tend to have a smooth, regular, rounded edge with a flat smooth base and surrounding mucosa that shows radiating folds. Malignant ulcers usually have irregular heaped-up or overhanging margins. Duodenal ulcers are characterized by the presence of a well-demarcated break in the mucosa that may extend into the muscularis propria of the duodenum.
3. chest radiograph may be useful to detect free abdominal air when perforation is suspected. On upper gastrointestinal (GI) contrast study with water-soluble contrast, the extravasation of contrast indicates gastric perforation.
4. Angiography may be necessary in patients with a massive GI bleed in whom endoscopy cannot be performed
5. A fasting serum gastrin level and secretin stimulation test should be obtained in certain cases to screen for Zollinger-Ellison syndrome.
6. Biopsy and Histologic Findings: The histology of gastric ulcer depends on its chronicity. The surface is covered with slough and inflammatory debris. Beneath this neutrophilic infiltration, active granulation with mononuclear leukocytic infiltration and fibrinoid necrosis may be seen. In chronic superficial gastritis, lymphocytes, monocytes, and plasma cells often infiltrate the mucosa and submucosa.

http://emedicine.medscape.com/article/181753-workup#c12

Pancreatitis back pain

Acute pancreatitis is one of several painful conditions, along with perforated duodenal ulcer and myocardial infarct, wherein visceral pain is referred to the spine.2 The back pain of pancreatitis is typically referred to the region of the tenth to twelfth thoracic vertebrae. From there the pain can radiate to the sub or mid scapular regions and to the left shoulder. The characteristic referral of pain to the back occurring with acute pancreatitis is due, in part, to the neurological phenomenon of referred pain, as well as to the position of the pancreas in the abdomen. The pancreas lies transversely across the abdomen in a retroperitoneal position against the posterior abdominal wall, behind the stomach and in front of the aorta, at the level of the second lumbar vertebrae. Pancreatic disease can cause back pain by direct stimulation of nociceptive fibers in the posterior abdominal wall which is well innervated by ventral branches of the intercostal nerves. The clinical phenomenon of referred pain is explained by the convergence theory. This theory suggests that afferent nerve fibers from muscles, joints, skin and viscera converge onto the same or adjacent cells in the spinal cord. A number of investigators have shown that visceral afferent fibers and small myelinated cutaneous afferent fibers converge onto lamina five cells of the spinal cord. The pancreas is innervated by the splanchnic nerves. These nerves are made up of preganglionic sympathetic fibers, arising in the spinal cord, that travel through the fifth to tenth thoracic sympathetic ganglia (sympathetic chain) to join at the tenth to twelfth thoracic interspace to become the greater splanchnic nerve. The lesser splanchnic nerve arises from sympathetic ganglia at the ninth and tenth thoracic levels. The splanchnic nerves, made up of preganglionic sympathetic fibers, travel through the diaphram to the celiac plexus from which postganglionic sympathetic fibers travel with the blood supply to the pancreas. The close relationship between the sympathetic innervation of the pancreas and the segmental innervation of joint, muscle and skin in the lower thoracic spine explains the frequent referral of pain to the lower thoracic region of the back with acute pancreatitis. Severe and chronic pancreatic pain, like that of carcinoma of the pancreas, is often relieved by an operation to cut the splanchnic nerves to the pancreas.

Musculoskeletal pain syndromes can present with pain patterns similar to those referred from diseases of the viscera. A number of musculoskeletal conditions can mimic the pain of acute pancreatitis. These include a thoracic posterior joint syndrome or an upper rectus abdominus trigger point. The absence of illness or signs of abdominal disease, and the presence of specific clinical signs implicating a musculoskeletal structure, suggest a musculoskeletal cause for the back pain rather than abdominal disease. A trigger point in the upper rectus abdominus can refer pain to the back below the scapulae and above the twelfth rib in the T7 to T1O region. 16 There will be tenderness at the abdominal trigger point and digital pressure at this point often refers pain to the back.

Signs of mechanical spine pain	Signs of back pain due to abdominal disease
Specific restriction of spinal motion	Pallor, fever, cold and clammy skin, jaundice
Local spinal tenderness (unilateral)	Abdominal guarding and tenderness
Pain provocation by specific examination procedures	Lack of pain localizing signs in the spine
	Abnormal vital signs (H.R., B.P., Resp.)
	Abnormal blood values (WCB, chemistry, enzymes)

https://www.ncbi.nlm.nih.gov/pmc/articles/PMC2484833/pdf/jcca00046-0013.pdf

MANAGEMENT OF BACK PAIN

No single form of therapy is effective for all forms of back pain. Patients with systemic causes must be treated with specific therapies effective for their underlying disease as discussed earlier. The following section provides guidelines for the management of nonspecific back pain.

■ Bed rest for more than 2 days is not helpful and may debilitate the patient. During the acute phase, patients are encouraged to ambulate as tolerated.

■ Relief of pain may be accomplished most safely with nonprescription analgesics or nonsteroidal medication. Spinal manipulation may be helpful during the first 4 weeks in patients without radiculopathy.

■ Low-stress aerobic activities can be started safely in the first 2 weeks of symptoms. Trunk muscle exercises should be delayed for at least 2 weeks.

■ Patients should be encouraged to return to usual activities, both vocational and recreational, as soon as possible.

Physical modalities

Physical modalities may be used to diminish symptoms for short periods. Such forms of therapy include ice massage, hot packs, diathermy, ultrasound, and transcutaneous electrical nerve stimulation. These therapies may be applied by patients themselves or by a therapist. They are most useful as an adjunct to other treatments rather than as sole therapy.

Exercise

Physical therapy, particularly in the form of therapeutic exercises, may be particularly helpful in controlling mechanical low back pain. As a generalization, patients with mechanical disorders of the disks prefer extension exercises, whereas those with stenosis prefer flexion exercises. In most circumstances, patients eventually perform a combination of both forms of exercise. Patients may feel worse before they feel better following an exercise program. In one study of patients with chronic low back pain, 2 months
was required before benefit was noted. The treating physician should find a physical therapist who is interested in taking care of patients with back pain and communicate concerns about patients to the therapist.

Rheumatology 6th Ed [2015]

RISK ASSESSMENT

Risk assessment for acute back pain — Among patients seen in primary care, less than 1 percent will have a serious systemic etiology that requires evaluation with immediate advanced imaging (cauda equina syndrome, metastatic cancer, and spinal infection). Patients with a high clinical suspicion for either vertebral osteomyelitis or epidural abscess should have MRI, a CT scan is a useful alternative to evaluate for epidural abscess, while radionuclide scans are an option to evaluate for osteomyelitis. When a concern for infection is present but not high, it is reasonable to evaluate patients with plain radiographs and ESR (or CRP). Patients with cancer or risk factors for cancer and neurologic deficits should have immediate imaging (start the evaluation with plain radiographs and ESR (or CRP)). In patients without neurologic deficits, the decision to image is based on risk. Patients with a positive radiograph should have appropriate further evaluation for malignancy (eg, evaluation for primary site, other metastatic disease). Patients with a positive ESR (or CRP) but negative plain radiograph should be further evaluated with MRI. Patients with suspected vertebral compression fracture should have plain radiographs for evaluation. Features in the history that indicate an increased risk for vertebral fractures include prolonged glucocorticoid use, advanced age, significant trauma or presence of contusion or abrasion, or recent mild trauma in a patient with a known diagnosis of or risk factors for osteoporosis.

Risk assessment subacute back pain — Patients who have not improved after four to six weeks of conservative therapy and who did not receive imaging on initial evaluation are reevaluated. Patients who have developed neurologic deficits or symptoms of infection in the interim should have imaging as noted above.

Patients who present initially with low back pain of more than four to six weeks duration should undergo the initial risk assessment as presented above.

In patients who had indications for immediate imaging and had negative findings, we do not repeat imaging in patients if symptoms are unchanged. Repeat imaging is indicated in patients with new or worsening symptoms or new concerns that develop in the interim. The modality will depend on the suspected diagnosis and the modality of the initial imaging exam.

Risk assessment chronic back pain — Patients who present initially with low back pain >12 weeks duration should undergo the risk assessment for acute and subacute back pain. In patients without specific concerns who have not received any imaging for indications noted above, if there is no improvement after 12 weeks, we generally image with a plain radiograph and consider the need for referrals for further evaluation and treatment.

Counseling patients who request imaging — Patients often expect that imaging will be ordered during their initial visit for back pain. Although it is not possible to provide a definitive physiologic diagnosis for low back pain in the majority of patients, clinicians can reassure patients without concerning history or physical exam findings that they appear to have "mechanical" or nonspecific low back pain, and that it is very unlikely that they have a serious underlying problem. Patients should be assured that improvement is to be expected and should be advised that:

- They are unlikely to have a serious underlying condition.
- Incidental imaging findings, unrelated to their pain, are common, and may lead to unnecessary further tests or interventions.
- Imaging is appropriate if they do not improve as expected.

http://www.uptodate.com/contents/evaluation-of-low-back-pain-in-adults?source=see_link#H22126536

Noninvasive Treatments for Acute, Subacute, and Chronic Low Back Pain: A Clinical Practice Guideline From the American College of Physicians 2017

Recommendation 1: Given that most patients with acute or subacute low back pain improve over time regardless of treatment, clinicians and patients should select nonpharmacologic treatment with superficial heat (moderate-quality evidence), massage, acupuncture, or spinal manipulation (low-quality evidence). If pharmacologic treatment is desired, clinicians and patients should select nonsteroidal anti-inflammatory drugs or skeletal muscle relaxants (moderate-quality evidence). (Grade: strong recommendation)

Recommendation 2: For patients with chronic low back pain, clinicians and patients should initially select nonpharmacologic treatment with exercise, multidisciplinary rehabilitation, acupuncture, mindfulness-based stress reduction (moderate-quality evidence), tai chi, yoga, motor control exercise, progressive relaxation, electromyography biofeedback, low-level laser therapy, operant therapy, cognitive behavioral therapy, or spinal manipulation (low-quality evidence). (Grade: strong recommendation)

Recommendation 3: In patients with chronic low back pain who have had an inadequate response to nonpharmacologic therapy, clinicians and patients should consider pharmacologic treatment with nonsteroidal anti-inflammatory drugs as first-line therapy, or tramadol or duloxetine as second-line therapy. Clinicians should only consider opioids as an option in patients who have failed the aforementioned treatments and only if the potential benefits outweigh the risks for individual patients and after a discussion of known risks and realistic benefits with patients. For second-line therapies, moderate-quality evidence showed that tramadol had a moderate effect on pain and a small effect on function in the short term (Grade: weak recommendation, moderate-quality evidence). Clinicians should therefore assess renovascular and gastrointestinal risk factors before prescribing NSAIDs and should recommend the lowest effective doses for the shortest periods necessary.

2017 http://annals.org/aim/article/2603228/noninvasive-treatments-acute-subacute-chronic-low-back-pain-clinical-practice

Nonpharmacologic Therapies

1. <u>Acute or Subacute Low Back Pain:</u>

•Exercise
•Acupuncture
•Superficial Heat
•Massage
•Low-Level Laser Therapy
•Lumbar Supports
•Others (transcutaneous electrical nerve stimulation (TENS), electrical muscle stimulation, inferential therapy, short-wave diathermy, traction, superficial cold, motor control exercise (MCE), Pilates, tai chi, yoga, psychological therapies, multidisciplinary rehabilitation, ultrasound, and taping)

2. <u>Chronic Low Back Pain</u>:

•Exercise
•Motor control exercise
•Pilates, Tai Chi or Yoga
•Psychological Therapies
•Multidisciplinary Rehabilitation
•Acupuncture or Massage
•Spinal Manipulation
•TENS or LLLT
•Lumbar Support
•Kinesio taping and sham taping
•Others (electrical muscle stimulation, interferential therapy, short-wave diathermy, traction, or superficial heat or cold).

<u>3.Radicular Low Back Pain</u>:

•Exercise
•Traction
•Other (ultrasound, MCE, Pilates, tai chi, yoga, psychological therapies, multidisciplinary rehabilitation, acupuncture, massage, spinal manipulation, LLLT, electrical muscle stimulation, short-wave diathermy, TENS, interferential therapy, superficial heat or cold, lumbar support, and taping)

TENS -Transcutaneous Electrical Nerve Stimulation, LLLT - Low-level laser therapy

2017 http://annals.org/aim/article/2603228/noninvasive-treatments-acute-subacute-chronic-low-back-pain-clinical-practice

Nonpharmacologic Therapies

low-level laser therapy

TENS

Tai Chi or Yoga

lumbar support

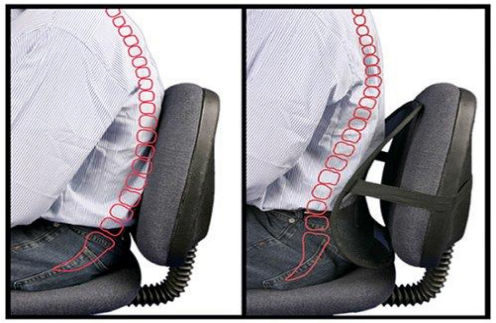

kinesio taping

motor control exercise

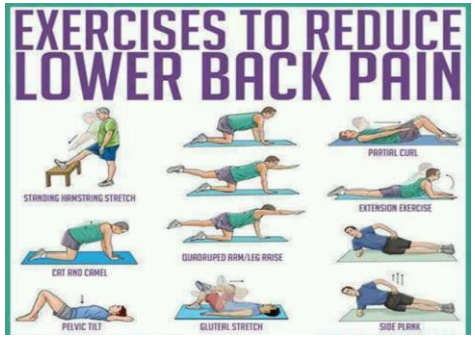

superficial heat

short-wave diathermy

ORAL DRUG THERAPY

Analgesics

Patients may benefit from acetaminophen. A slow-release form of the drug may allow a more prolonged analgesic effect in patients with back pain. The drug has a synergistic effect with NSAIDs and may be used in combination to increase analgesia without increasing toxicity. Narcotic analgesia should be reserved for patients with severe, functionally limiting pain and be used along with NSAIDs, other adjuvant analgesics, and a bowel regimen. Stronger narcotic analgesia should be reserved for patients who are unable to perform activities of daily living because of persistent pain.

Nonsteroidal antiinflammatory drugs

NSAIDs have analgesic properties in low doses and antiinflammatory properties at higher doses. The onset of action of the agents is important. With acute back pain, a rapid onset of action is important to control the symptoms quickly. With chronic pain, the onset of action is not as important as efficacy and safety over extended periods. NSAIDs as a class of agents are effective therapy for low back pain. No specific selection criteria for the choice of a single agent have been established. Cyclooxygenase-2 (COX-2)-selective inhibitors are indicated for the treatment of low back pain in individuals with a history of peptic ulcer disease or gastrointestinal intolerance of dual COX-1/COX-2 inhibitors.

Muscle relaxants

Muscle relaxants used for patients with low back pain work centrally to affect the activity of the muscle stretch reflexes. The combination of an NSAID and a muscle relaxant offers significant relief of pain when compared with other combinations of therapies, including those with narcotics. The major side effects of muscle relaxants are drowsiness, headache, dizziness, and dry mouth.

Neuropathic pain agents

Tricyclic antidepressants have been shown in double-blind studies to relieve chronic pain. Low doses may be adequate to control symptoms. These drugs do not work immediately and may need to be continued for a number of weeks before decreased symptoms are noted. Selective serotonin reuptake inhibitors (sertraline, fluoxetine) are not as effective as tricyclics for relief of chronic pain. Mixed norepinephrine and serotonin reuptake inhibitors (venlafaxine and duloxetine) seem to have a more effective role in the management of chronic pain. The second major class of neuropathic pain agents includes antiepileptic medications such as pregabalin, gabapentin, and carbamazepine. Neuropathic pain medications have a potential role when pain is mediated by both peripheral and central mechanisms. Chronic axial low back pain may also benefit from a trial of these agents. Strong evidence for the use of these agents is lacking, but judicious use can improve pain and quality of life and help restore sleep.

Rheumatology 6th Ed [2015]

INJECTION THERAPY

Local or regional anesthesia given by injection is part of the therapeutic regimen for some patients with low back pain. The region injected may be an area of local trauma or a myofascial trigger point. Trigger points are areas of the muscle that are painful at rest, prevent full lengthening of the muscle, weaken the muscle, refer pain in the muscle group on direct palpation, and cause a local contraction when palpated.

Epidural injections

Epidural corticosteroid injections are used for patients with radicular pain who do not respond to less invasive management. The efficacy of these injections for the treatment of herniated disks and spinal stenosis with radiculopathy has been questioned, although they have been found to be effective in some patients. Benefits include decreased leg pain and more rapid return of sensory function. Epidural steroids may be administered via the interlaminar, transforaminal, and caudal routes. Fluoroscopic guidance improves the likelihood of delivering medication to the intended target.

Facet joint injection

Facet syndrome can mimic radicular pain. Diagnosis of facet syndrome is based on diagnostic anesthetization of the joint or its innervation. Corticosteroids can be injected to decrease pain. These injections are done under fluoroscopic control to document appropriate placement of the needle. A facet joint receives innervation by the medial branches of the dorsal rami from the same level and the level above. If facet syndrome is confirmed on the basis of time-dependent medial branch anesthetic block, the medial branches can be denervated via radiofrequency ablation.

Surgical treatment

A small percentage of individuals with low back pain require surgical intervention to improve their condition. Indications for surgery vary according to the patient's characteristics but include sphincter and sexual dysfunction secondary to compression of the conus medullaris or cauda equina; severe radicular symptoms, particularly if progressive neurologic motor deficits are present; and radicular symptoms failing to respond to conservative management. Selection of the operative procedure is determined by the characteristics of the lesions and the skill of the surgeon with the specific technique. With spinal stenosis, the success of surgical approaches depends on adequate decompression of areas of absolute stenosis and good judgment with respect to the adequacy of decompression of areas of relative stenosis. Surgery is most effective when patients have a clinical picture dominated by manifestations of nerve compression. The most common technical problem is inadequate neural decompression. Comorbid conditions, including hip arthritis, osteoporosis, and cardiovascular disease, are associated with persistent pain after surgical correction. Surgery for patients with radicular pain from a herniated disk primarily involves decompression; removal of the protruded, extruded, or sequestered disk material; and inspection and release of the tethered nerve root. Indications for concomitant spinal fusion remain controversial. Patients with spondylolisthesis, degenerative scoliosis, a history of previous surgery, segmental instability, or predominantly axial pain with concordant diskographic findings are possible candidates for concomitant fusion.

Rheumatology 6th Ed [2015]

There is general agreement that patients with acute nonspecific spine pain or nonlocalizable lumbosacral radiculopathy (without neurologic signs or significant neurologic symptoms) require only conservative medical management. Patients should abstain from heavy lifting or other activities that aggravate the pain.

Approach to the Treatment of Nonspecific Acute Low Back Pain

First visit

Patient education

- Reassure the patient that the prognosis is often good, with most cases resolving with little intervention
- Advise the patient to stay active, avoiding bed rest as much as possible, and to return to normal activities as soon as possible
- Advise the patient to avoid twisting and bending

Initiate trial of a nonsteroidal anti-inflammatory drug or acetaminophen

Consider a muscle relaxant based on pain severity

Consider a short course of opioid therapy if pain is severe

Consider referral for physical therapy (McKenzie method and/or spine stabilization) if it is not the first episode

Second visit*

Consider changing to a different nonsteroidal anti-inflammatory drug

Consider referral for physical therapy (McKenzie method and/or spine stabilization) if not done at initial visit

Consider referral to a spine subspecialist if pain is severe or limits function

*—*Two to four weeks after the initial visit, if the patient has not significantly improved.*

Nonsteroidal anti-inflammatory drugs (NSAIDs) are often first-line therapy for low back pain.

Moderate-quality evidence shows that non-benzodiazepine muscle relaxants (e.g., cyclobenzaprine, tizanidine, metaxalone) are beneficial in the treatment of acute low back pain. Most pain reduction from these medications occurs in the first seven to 14 days, but the benefit may continue for up to four weeks. Because all muscle relaxants have adverse effects, such as drowsiness, dizziness, and nausea, they should be used cautiously.

Opioids are commonly prescribed for patients with severe acute low back pain. Although epidural steroid injections are not beneficial for isolated acute low back pain, they may be helpful for radicular pain that does not respond to two to six weeks of noninvasive treatment.

Bed rest should not be recommended for patients with nonspecific acute low back pain.

http://www.aafp.org/afp/2012/0215/p343.html

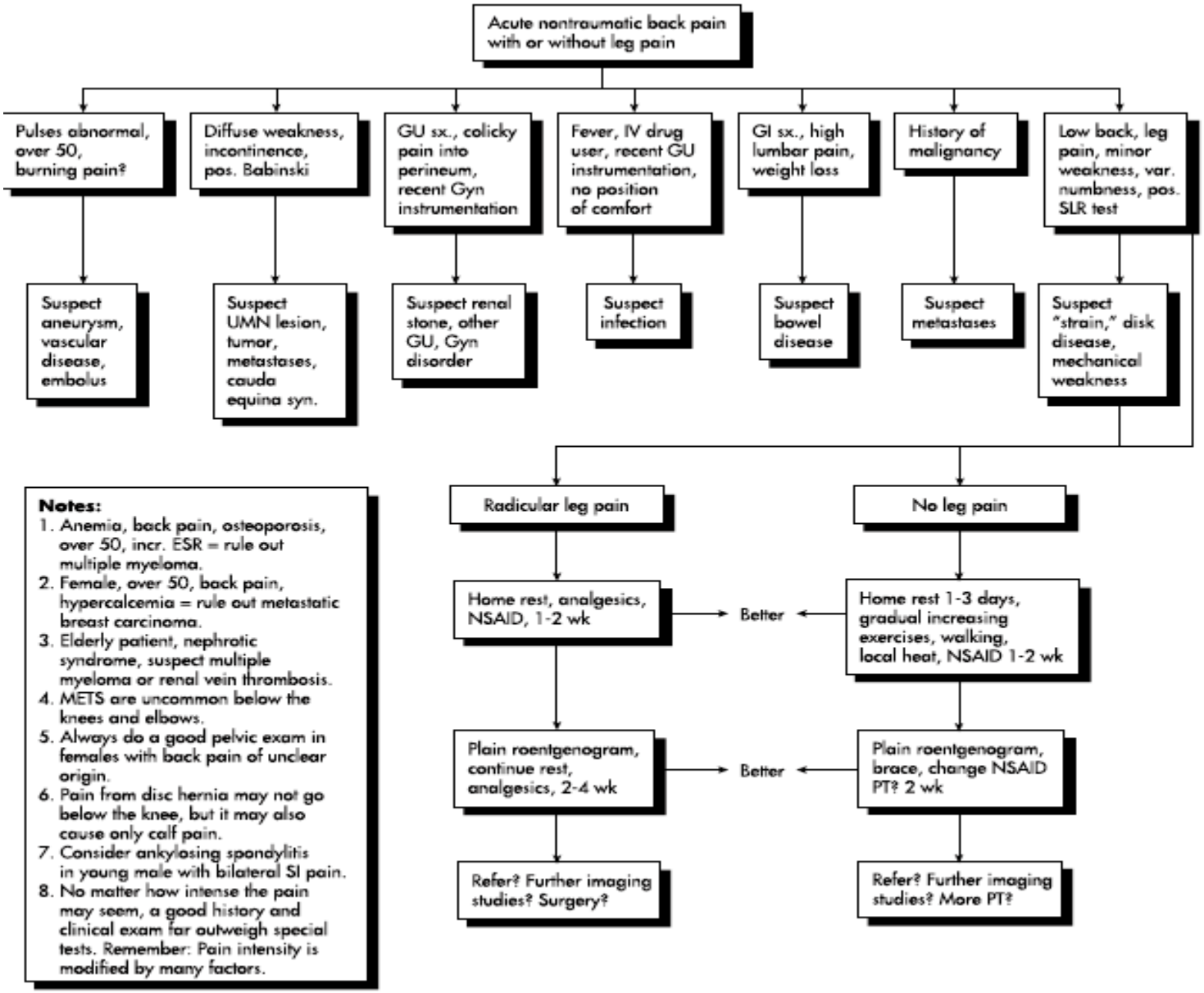

Algorithm for low back and/or leg pain. *GI*, Gastrointestinal; *GU*, genitourinary; *IV*, intravenous; *METS*, metabolic equivalents; *NSAID*, nonsteroidal anti-inflammatory drug; *PT*, physical therapy; *SI*, sacroiliac; *SLR*, straight-leg raising; *UMN*, upper motor neuron. (From Mercier LR: *Practical orthopedics*, ed 2, St Louis, 2000, Mosby.)

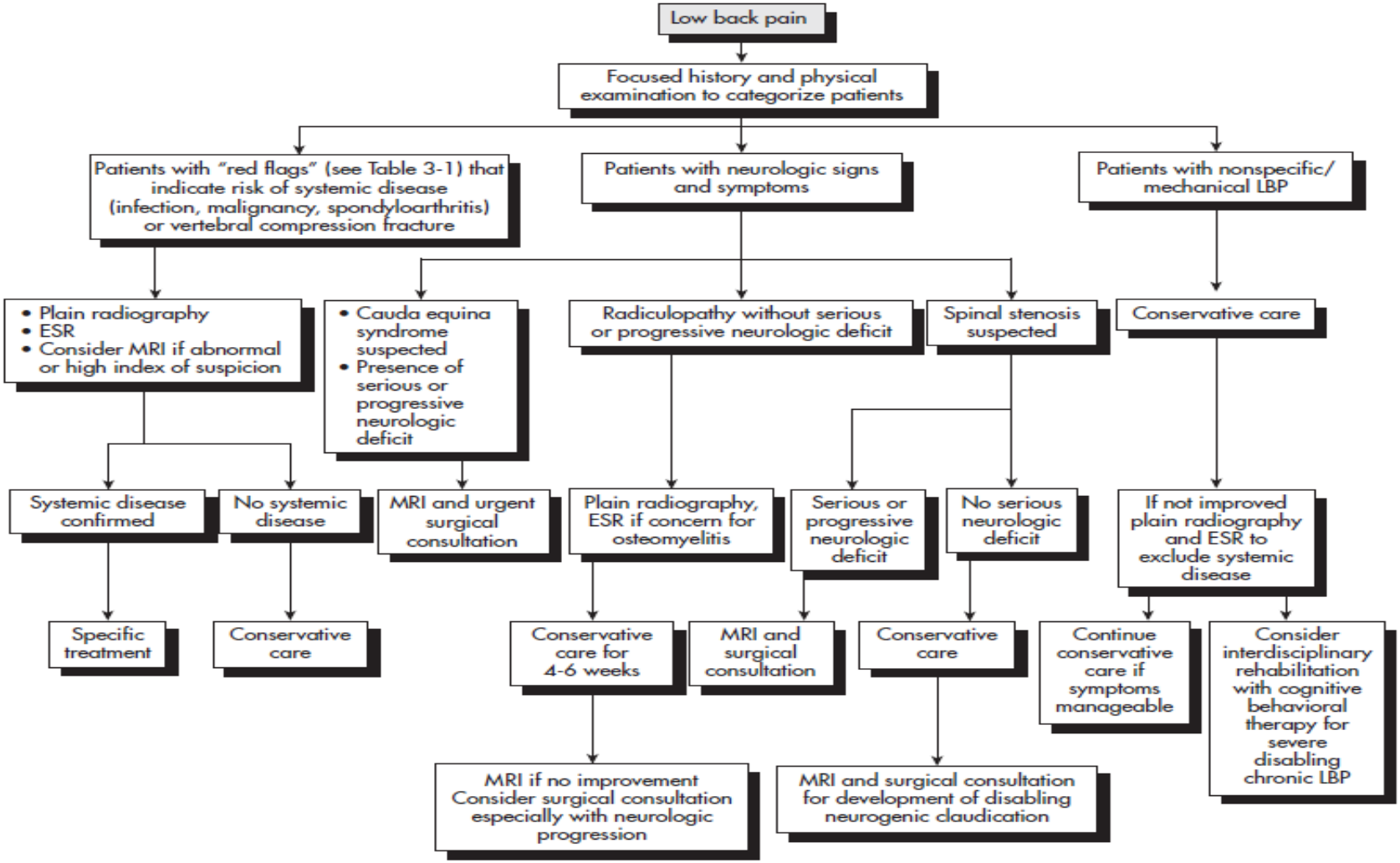

FIGURE 3-26 Algorithm for the differential diagnosis and treatment of low back pain. *ESR*, erythrocyte sedimentation rate; *LBP*, low back pain; *MRI*, magnetic resonance imaging. (Rom Firestein GS, Budd RC, Gabriel SE, et al: *Kelly's textbook of rheumatology*, ed 9, Philadelphia, 2013, Saunders.)

TABLE 3-1 Red Flags for Potentially Serious Conditions

Possible Fracture	Possible Tumor or Infection	Possible Cauda Equina Syndrome
From Medical History		
Major trauma, such as vehicle accident or fall from height	Age over 50 or under 20 yr	Saddle anesthesia
Minor trauma or even strenuous lifting (in older or potentially osteoporotic patient)	History of cancer	Recent onset of bladder dysfunction, such as urinary retention, increased frequency, or overflow incontinence
	Constitutional symptoms, such as recent fever or chills or unexplained weight loss	Severe or progressive neurologic deficit in the lower extremity
	Risk factors for spinal infection: recent bacterial infection (e.g., urinary tract infection), intravenous drug abuse, or immune suppression (from steroids, transplant, or human immunodeficiency virus)	
	Pain that worsens when supine; severe nighttime pain	

SUMMARY AND RECOMMENDATIONS

●A focused history and physical examination are sufficient to evaluate most patients with back pain of less than four weeks duration. The history and physical examination should identify features that suggest that imaging and/or other evaluations are indicated.

●The majority of patients with low back pain of less than four weeks duration do not require imaging. Among patients seen in primary care, less than 1 percent will require immediate advanced imaging (eg, magnetic resonance imaging [MRI] or computed tomography

•Any patient with symptoms of spinal cord or cauda equina compression or progressive and/or severe neurologic deficits should have immediate MRI for further evaluation and urgent specialist referral. Such symptoms and signs include new urinary retention, incontinence from bladder overflow, new fecal incontinence, saddle anesthesia, and significant motor deficits not localized to a single unilateral nerve root

•Other patients who may require imaging on initial evaluation include those with a high suspicion for spinal infection, a current or recent history of cancer, major risk factors for cancer, and those with suspected vertebral compression fracture

●Patients who have not improved after four to six weeks of conservative therapy and who did not receive imaging on initial evaluation are reevaluated:

•Patients with persistent symptoms due to a lumbosacral radiculopathy or spinal stenosis who are candidates for and are interested in invasive therapies (eg, surgery or epidural injection for radiculopathy) should have an MRI for further evaluation.

•In patients with low back pain who have risk factors for cancer, we evaluate with erythrocyte sedimentation rate (ESR) or C-reactive protein (CRP) and plain radiographs.

•Other patients that may need imaging include those with concerns for ankylosing spondylitis and osteoarthritis. (

•In other patients where there are no concerns for a particular etiology, we generally treat with conservative therapy for another eight weeks.

●For patients without concerns for a particular etiology who have not improved after 12 weeks total, we generally image with a plain radiograph and consider referrals for further evaluation and treatment.

http://www.uptodate.com/contents/evaluation-of-low-back-pain-in-adults?source=see_link#H22126536

The End